

# Acquired Adult Flatfoot (Posterior Tibial Tendon Dysfunction)

Dr. Courtney Grimsrud  
CU Orthopedic Surgery - Foot & Ankle

---

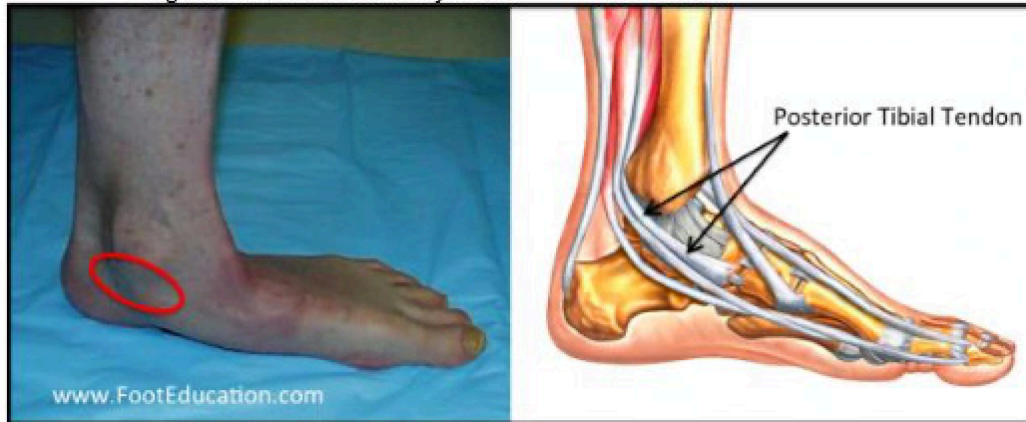
## Summary

Chronic posterior tibial tendon insufficiency can result in acquired adult flatfoot deformity, also referred to as **pes planus**, a fallen arch, an abnormally pronated foot, or simply flatfoot deformity. This is a chronic foot condition where the soft-tissues (including the posterior tibial tendon, deltoid and spring ligaments) on the inside aspect of the foot and ankle are subject to repetitive load during walking and standing. Over time, these structures may become painful, swollen, or incompetent. When these supporting structures fail, the result is a change in the alignment of the foot. This condition is typically associated with a progressive flatfoot deformity, leading to increased strain on the supporting structures on the inside of the ankle, and loading through the outer aspect of the ankle and foot. Both the inside and outside of the ankle can become painful, resulting in significant disability. This condition can often be treated without surgery by strengthening the involved muscles and tendons, or with bracing. When non-operative treatment fails, surgery can improve alignment and pain through soft tissue transfers, realignment of bones or fusions. Alignment and function can be restored, however, the time to maximal improvement is typically six months to a year. It is also important to realize that not all flatfoot deformities result from problems with the posterior tibial tendon. A flat foot can be a normal variant and does not necessarily need treatment if it is non-painful and does not limit function. In other words, some people have “normal appearing arches,” some people have “high arches,” and other people have “pronated, or flat appearing arches.”

## Clinical Presentation

Patients with acquired adult flatfoot deformity typically provide a history of longstanding pain at the inside of the foot and ankle, resulting in progressive, painful flatfeet (Figure 1). Symptoms of pain may have developed gradually as a result of overuse, or they may be traced to one injury. Typically, the pain localizes to the inside (medial) aspect of the ankle, under the medial malleolus (see circle in Fig. 1). However, some patients will also experience pain over the outside (lateral) aspect of the hind-foot, because of the resultant deformity and pressure or impingement on the lateral structures of the foot and ankle. This usually occurs later in the course of the condition. Patients may walk with a limp or, in advanced cases, be disabled due to pain.

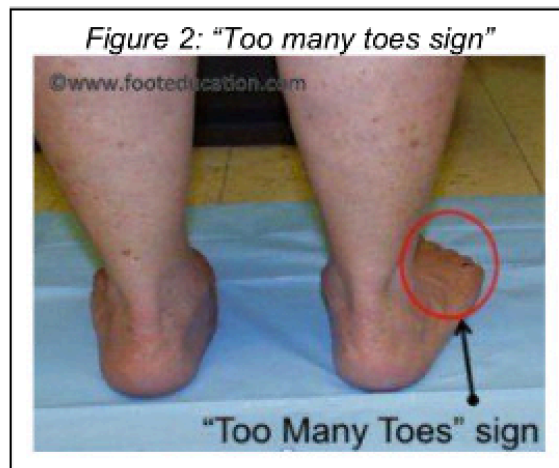Figure 1: Flatfoot deformity and Location of Posterior Tibial Tendon



### Physical Examination

Looking at the patient when they stand will usually demonstrate a flatfoot deformity or a pronated foot (marked flattening of the medial longitudinal arch). The front part of the foot (forefoot) is often splayed out to the side, leading to the presence of a “too many toes” sign (Figure 2). This sign is present when the toes can be seen from directly behind the patient.

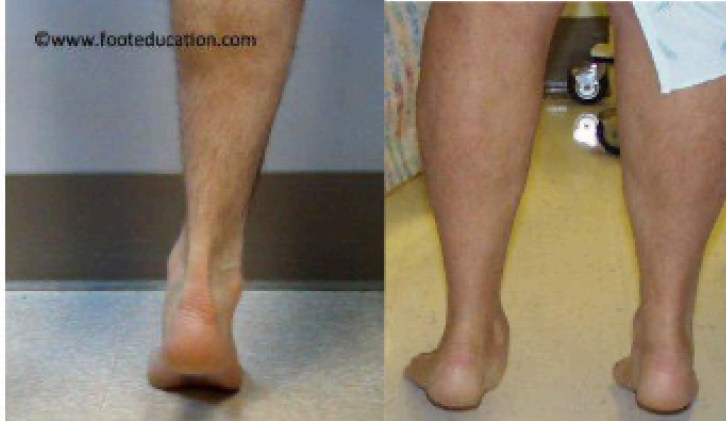Figure 2: “Too many toes sign”



Posterior tibial tendon dysfunction may affect the patient's walking, as the patient's dysfunctional posterior tibial tendon can no longer stabilize the arch of the foot when weight is placed on it. There is often tenderness to touch and swelling over the inside of the ankle just below the bony prominence (the medial malleolus). There may also be pain in the outside aspect of the ankle with palpation. This pain originates from impingement or compression of two tendons between the outside ankle bone (fibula) and the heel bone, (calcaneus) when the patient is standing.

A single-leg heel rise test is used to determine whether the posterior tibial tendon is intact or whether it has become dysfunctional. If the patient can stand on one foot and raise the heel off of the ground 3-5 times, then this suggests that the posterior tibial tendon is intact (Figure 3 [left]). If they are unable to do this, the posterior tibial tendon is likely dysfunctional (Figure 3 [right]).

Figure 3: Ability to do a single leg heel rise (left picture); Inability to do a single leg heel rise (right picture)



### Imaging Studies

X-Rays of the foot taken while weight bearing allows the physician to assess the extent of the flatfoot deformity (Figures 4a and 4b).

MRI is usually not indicated for patients with acquired adult flatfoot deformity, as the diagnosis and the classification can be established on physical examination. However, if there are other clinical signs that suggest either a problem within the ankle, the subtalar joint, (intra-articular pathology) or another source of pain, then an MRI may be indicated.

Figure 4a: Normal Foot X-Ray

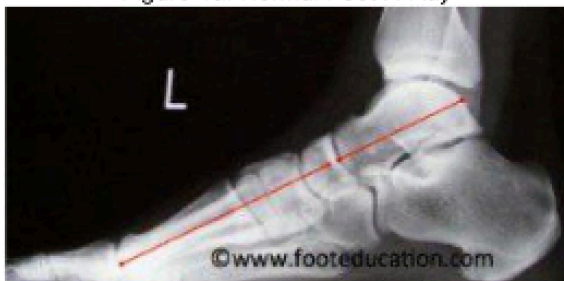
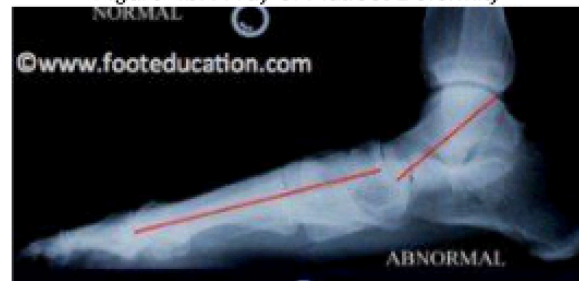
Figure 4b: X-ray of Flatfoot Deformity



### Classification

Acquired adult flatfoot deformity has been classified into four categories.

- **First Stage:** The first stage represents inflammation and symptoms originating from an irritated posterior tibial tendon, which is still functional.
- **Second Stage:** Stage two is characterized by a change in the alignment of the foot, noted on observation while standing (see above photos). The deformity is supple, meaning the foot is freely movable and a “normal” position can be restored by the examiner. Stage two is also associated with the inability to perform a single-leg heel rise.
- **Third Stage:** The third stage represents a flatfoot deformity that becomes stiff because of arthritis. Prolonged deformity causes irritation to the involved joints, resulting in arthritis and the inability to correct the foot to a normal position.

• **Fourth Stage:** The fourth phase is a flatfoot deformity where deformity, stiffness and/or arthritis extends to involvement of the ankle joint. This occurs when the deltoid ligament, the major supporting structure on the inside of the ankle, fails to provide support. The ankle becomes unstable and will demonstrate a tilted appearance on X-ray. Failure of the deltoid ligament results from an inward displacement of the weight bearing forces. When prolonged, this change can lead to ankle arthritis.

The vast majority of patients with acquired adult flatfoot deformity have reached stage 2 by the time they seek treatment from a physician.

### **Treatment: Non-Operative Treatment**

Nonoperative treatment of stage 1 and 2 acquired adult flatfoot deformity can be successful. General components of the treatment include:

- The use of comfort shoes.
- The use of an over-the-counter (store-bought) or custom made orthotic insoles to support the arch
- Activity modification to avoid exacerbating activities and strengthening to build support.
- Weight loss if indicated.



Specific components of treatment that over time can lead to marked improvement in symptoms include:

- A high repetition, low resistance strengthening program
- Appropriate bracing or a medial longitudinal arch support.

If the posterior tibial tendon is intact, a series of exercises aimed at strengthening the elongated and dysfunctional tendon can be successful. In stage 1 or 2 deformities, this may be combined with an ankle brace and an off-the-shelf or custom made orthotic insert which may help to support the arch.

### **Treatment: Operative Treatment**

Operative treatment may be indicated for those patients that have stage 2 or higher dysfunction and have failed nonoperative management. The principles of operative treatment of stage 2 deformities include:

- Transferring another tendon to help serve the role of the dysfunctional posterior tibial tendon (usually the flexor digitorum or flexor hallucis longus is transferred)
- Restoring the shape and alignment of the foot. This moves the weight bearing axis back to the center of the ankle.

Changing the shape of the foot can be achieved by one or more of the following procedures:

- Cutting the heel bone and shifting it to the inside (Medializing calcaneal osteotomy)
- Lateral column lengthening restores the arch and overall alignment of the foot.
- Medial column stabilization, which stiffens the ray of the big toe to better support the arch.
- Lengthening of the Achilles tendon or Gastrocnemius. This will allow the ankle to move adequately once the alignment of the foot is corrected.

Stage 3 acquired adult flatfoot deformity may be treated operatively with a hindfoot fusion (arthrodesis). This is done with either a double or triple arthrodesis – fusion of two or three of the joints in hindfoot through which the deformity occurs. This is typically performed in such a way that the underlying foot deformity is corrected first.

### **Potential Surgical Complications**

- Wound-healing problems
- Infection
- Failure to heal bone (non-union) that has been cut or joints that have been fused
- Deep Vein Thrombosis (DVT), (blood clot forms in the leg)
- Pulmonary embolism, (blood clot travels to the lungs)
- Neurological injury
- Vascular Injury
- Continued pain and deformity
- Recurrence of deformity and pain

### **Recovery from Surgery**

The recovery from surgery is dependent upon the particular combination of procedures that are performed. However, if cutting and repositioning bones or fusing joints is required, (as it usually is) a typical recovery would be:

- Healing Phase: 6 weeks of non-weightbearing is usually required
- Rehabilitation Phase: a period of gradual rehabilitation following the Healing Phase.

---

The information contained in this handout is copyrighted by FootEducation LLC. It may be reproduced in small quantities for non commercial educational purposes. This information is for general education purposes only. It should not be used without guidance from a licensed healthcare provider. Handout Courtesy of [www.FootEducation.com](http://www.FootEducation.com)