Correction of Leg Length Discrepancy and ACL Instability in Fibular Hemimelia: Technique for an Effective Combined Approach with PRECICE Nail

Orthopedics
UNIVERSITY OF COLORADO

B. Reeves, MD[1], B. Roper, MD[1,2], R. Salton, BS[2], J. Albright, MD[1,2], N. Hadley-Miller, MD[1,2]
[1]University of Colorado Denver, Anschutz Medical Campus, Department of Orthopedics, Aurora, CO
[2]Children's Hospital Colorado, Department of Orthopaedics, Aurora, CO

Children's Hospital Colorado

INTRODUCTION

- Fibular hemimelia is a congenital deficiency of the fibula, commonly associated with hypoplasia or dysplasia of the ipsilateral femur, tibia and/or foot. [1]
- The incidence of hemimelia is reported between 5.7-20 cases per 1 million live births.[2]
- Fibular hemimelia is associated with several extremity malformations: Significant leg length discrepancy (>2cm), lateral femoral condyle hypoplasia, genu valga, tarsal coalition, cleft foot, ball-and-socket type ankle and anterior cruciate ligament (ACL) deficiency.[5,6,9]
- Externally controlled internal lengthening motorized magnetic devices such as the PRECICE Nail have been found to be safe and reliable methods for guided femoral and tibial bone lengthening.[3,4]
- ACL deficiency has an incidence of up to 95% in patients with hemimelia, however, there is no consensus regarding the importance, feasibility or optimal technique for ACL reconstruction in this pediatric population.[7,8]

AIMS

- **Aim 1:** To demonstrate adequate lengthening and acceptable correction of leg length discrepancy with utilization of PRECICE Nails (NuVasive Inc., San Diego, CA).
- **Aim 2:** To detail a surgical technique guide for ACL reconstruction in patients who also underwent either femoral or tibial lengthening with a PRECICE Nail.
- **Aim 3:** Compare clinical outcomes in patients with fibula hemimelia who underwent limb lengthening and ACL reconstruction surgery.

METHODS

Study Design: Single institution case series

Study Subjects: Patients with congenital fibular hemimelia who underwent limb lengthening via externally controlled internal motorized intramedullary nail implantation of either the femur or tibia with ACL reconstruction at Children's Hospital Colorado between 2012 and 2022.

- Inclusion criteria: Age <18 years old, fibular hemimelia, congenitally short tibia and/or femur, ACL deficient knee, use of PRECICE Nail and underwent ACL reconstruction.
- Data Collection: Patient demographics were obtained by chart review. Lower extremity limb lengths were obtained from calibrated standing hip to ankle X-rays using EPIC PACS. Measurements were taken from x-rays pre-operatively and post-operatively up to 4 years:
  - ➢Significant leg length discrepancy was characterized as an inequality of greater than or equal to 2cm.[9]
  - ➢Knee instability was defined as subjective symptoms of instability and at least grade 2 pivot shift and grade 2A Lachman's test.

Analysis: Descriptive

TECHNIQUE

Figure 1: Physeal sparing ACL reconstruction with IT band.

Figure 2: Femoral and tibial bone tunnels for ACL quadriceps graft

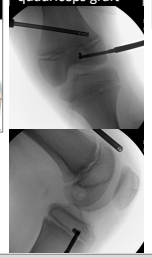

Figure 3: Osteotomy and placement of Tibial PRECICE Nail

Figure 4: Syndesmosis fixation

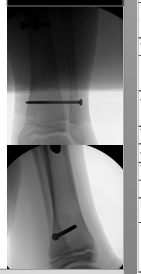

Table 1: Demographic and Clinical Characteristics of the Study Group

Participant ID	1	2	3	4	5	Average
Age at Time of Surgery (years)	11.9	11.7	8.9	10.4	9.8	10.5
Age at Time of Diagnosis (years)	0.4	2	3.4	0.7	0.4	1.4
Side of Hemimelia	Left	Left	Left	Left	Right	
Congenitally Short Bone	Tibia	Tibia	Femur	Femur	Tibia	
Associated Anomolies	Polydactyly	N/A	N/A	N/A	Polydactyly	
Plays Running/Jumping/Cutting Sports	No	Yes	Yes	Yes	Yes	
Previous Epiphysiodesis/Hemiepiphysiodesis	Yes, Left	Yes, Left	Yes, Left	Yes, Left	No	

Figure 2: 14-year-old male with left fibular hemimelia and left tibial hypoplasia with congenital leg length discrepancy and ACL deficiency.

A) Initial presentation at 22 months of age demonstrating left fibular hypoplasia and 2.8cm of shortening of the left lower extremity compared to the right.
B) Final pre-operative x-rays at 11 years 7 months of age demonstrating 3.5cm of shortening of the left lower extremity.
C) MRI of the left knee at 9 years 2 months demonstrating absence of the ACL..
D) Initial post-operative left lower extremity x-rays at 11 years 8 months of age demonstrating medial distal femoral hemiepiphysiodesis, PRECICE nail with tibial and fibular osteotomies and syndesmosis screw fixation.
E) Final controlled lengthening lower extremity x-rays at 11 years 11 months of age after 5cm of controlled left tibial lengthening resulting in +0.6cm of lengthening of the left lower extremity compared to the right.
F) Last follow-up lower extremity x-rays at 13 years 3 months of age demonstrating 1.3cm of lengthening of the right lower extremity compared to the left.

RESULTS

Table 2: Summary of Surgical Characteristics and Clinical Outcomes

	Patient ID	1	2	3	4	5	Average
Bone Lengthened		Tibia	Tibia	Femur	Femur	Tibia	
Pre-operative Total LLD (cm)	Femur	1.1	1.5	2.8	3.3	-0.9	1.9
	Tibia	6.9	1.3	0.1	2	3	2.7
Total Initial LLD (cm)		8	2.8	2.9	5.3	2.1	4.22
Post-operative Total LLD (cm)	Femur	2	2.6	0	0	0.1	0.94
	Tibia	2.2	-1.3	1.9	3.1	2.2	2.14
Amount Lengthened (cm)	Femur			5.9	8		6.95
	Tibia	5	5			5	5
Total Residual LLD (cm)		4.2	1.3	1.9	3.1	2.3	2.56
ACL Reconstruction		Yes	Yes	Yes	Yes	Yes	
Time From Diagnosis to Surgery		11.5	9.7	5.5	9.7	9.4	9.16
Length of Follow-up (years)		1.1	1.5	4.1	2.7	1.7	2.22
Duration of Hardware Implantation (years)		1.4	2.7	3.1	1.2	3.9	2.46
Complications		Early Fibular Consolidation	N/A	N/A	Knee Arthrofibrosis	Early Fibular Consolidation	

MAJOR FINDINGS:

- Average age at the time of surgery was 10.5 years (8.91 years to 11 .91 years).
- Average total pre-operative leg length discrepancy: 4.22 cm (2.1 to 8 cm).
- Overall residual leg length discrepancy following guided growth was 2.56 cm (1.3 to 4.2 cm) with an average follow-up of 2.2 years (range 1.1 to 4.1 years).
- PRECICE Nail related limb lengthening complications included 2 patients with early fibular consolidation and one patient with knee arthrofibrosis. All three of these patients required additional surgery for repeat fibular osteotomy and closed manipulation, respectively.
- ACL reconstruction with either physeal sparring IT band construct or quadriceps tendon autograft reported subjective and objective knee stability at follow-up and were able to return to sport.

CONCLUSION

- PRECICE nails provide reliable guided limb lengthening .
- Persistent leg length discrepancy is not uncommon following limb lengthening, and clinically insignificant leg length difference can commonly be achieved through epiphysiodesis or additional lengthening procedures.
- ACL reconstruction is routinely feasible at the time of externally controlled internal lengthening motorized magnetic intramedullary nail insertion.

FUTURE DIRECTIONS

- Include subjective patient reported outcomes with clinical outcome data.
- Compare clinical outcomes of titanium PRECICE nails with stainless steel STRYDE nails in patients with hemimelia.

References:

1. Paley, D. Surgical Reconstruction for Fibular Hemimelia. *J Child Orthop.* 2016; 10:517-583.
2. Paulozzi L, Mejia M.A., Grace L.M. Prenatal diagnosis of a congenital postaxial longitudinal limb defect: a case report. *Obstet Gynecol Int.* 2010; 2010:825639. Doi: 10.1155/2010/825639.
3. Dodds L., Specht S.C., Standard S.C., Herzenberg J.E. Internal Lengthening Device for Congenital Femoral Deficiency and Fibular Hemimelia. *Clin Orthop Relat Res.* 2014 Dec; 472(12): 3860-3868. Doi: 10.1007/s11999-014-3772-3.
4. Kiadis A.D., Pallios Ir., Wright J., Gaudine D., Calder P. Pediatric Lower Limb Lengthening Using the PRECICE Nail: Our Experience with 50 Cases. *Pediatr Orthop.* 2021 Jan; 41(1): e64-e69. Doi: 10.1097/BPO.0000000000001672
5. Mishima K., Kitoh, H., Iwata K., Matsushita M., Nishida Y., Hattori T., Ishiguro N. Clinical Results and Complications of Lower Limb Lengthening for Fibular Hemimelia; A Report of Eight Cases. *Medicine (Baltimore).* 2016 May;95(21): e3787. Doi: 10.1097/MD.0000000000003787.
6. Young P., Manseau B. Internal Derangement of the Knee in Fibular Hemimelia: Radiographic and MRI findings. *The Knee.* 2014 Mar;21(1): P749-756. Doi: https://doi.org/10.1016/j.knee.2014.02.017
7. Roux M.D., Carlioz H. Clinical Examination and Investigation of the Cruciate ligaments in Children with Fibular Hemimelia. *Journal of Pediatric Orthopaedics.* 1999 Mar; 19(2): 247-251.
8. Crawford D.A., Tompkins B.J., Baird G.O., Caskey P.M. The Long-Term Function of the Knee in Patients with Fibular hemimelia and Anterior Cruciate Ligament Deficiency. *The Bone and Joint Journal.* 2012 Mar; 94(3): 328-333. Doi: 10.1302/0301-620X.94B3.27997
9. Knutson G.A. Anatomic and functional leg-length inequality: A review and recommendation for clinical decision-making. Part I, anatomic leg length inequality: prevalence, magnitude, effect and clinical significance. *Chiropr Osteopat.* 2005; Jul;13(11): Doi: 10.1186/1746-1340-13-11.
10. Lee D.H., Kim S., Lee J., et al A comparison of the device-related complications of intramedullary lengthening nails using a new classification system. *BioMed Res Int.* 2017;1-9.
11. Al-Hadithy N., Dodds A.L., Akhtar K.S.N., Gupta C.M. Current concepts of the management of anterior cruciate ligament injuries in children. *Bone Joint Journal.* 2013 Nov;95-B(11):1562-9. Doi:10.1302/0301-620X.95B11.31778.
12. Misuta K, Kubota K, Shirasaki M., et al. The conservative treatment of complete tears of the anterior cruciate ligament in skeletally immature patients. *J Bone Joint Surg.* 1995;77-B:890-894
13. Gabos P.G., El Rassi G., Pahys J. Knee reconstruction in syndromes with congenital absence of the anterior cruciate ligament. *J Pediatr Orthop.* 2005;25:210-214.
14. Koelin A., Hulin P., Carlioz H. Congenital aplasia of the cruciate ligaments. *J Bone Joint Surg.* 1986;68-B:827-828.
15. Lee J.J., Oh W.T., Shin K.Y., Ko M.S., Choi C.H. Ligament reconstruction in congenital absence of the anterior cruciate ligament: A case report. *Knee Surg Relat Rev.* 2011 Dec;23(4):240-243. Doi: 10.5792/ksrr.2011.23.4.240.