Case Report: Irreducible Knee Dislocation in a 15-year-old due to avulsed MCL

Orthopedics
UNIVERSITY OF COLORADO

Adam Peszek[1], Jason Rhodes[1 2], Alex Lencioni[1], Brady Williams[1]

1. Department of Orthopedics, University of Colorado, Aurora, CO, USA; 2. Department of Orthopedics, Children's Hospital Colorado, Aurora, CO, USA

Children's Hospital Colorado

Abstract

- Case of a 15-year-old male, sustained a posterolateral knee dislocation after a motor-bike accident
- Failed multiple closed reduction attempts
- Arthroscopy revealed avulsed MCL wrapped over the medial femoral condyle causing a mechanical block to reduction.
- The knee was immediately clinically reduced following removal of the MCL from the articular space intraoperatively.
- To the authors' knowledge, interposition of an avulsed MCL as a mechanical block to reduction of a dislocated knee has not previously been described in the literature.

Introduction

- Knee dislocations are a rare, typically high-energy traumatic injury
- True emergency in orthopedics due to risk of compromised blood supply.
- Knee dislocations account for between 1-10 per 100,000 hospital admissions
  - Less than 0.02% of all musculoskeletal injuries
  - 0.5 percent of all joint dislocations[1 2 3].
- Knee dislocations classified based on the direction anterior, posterior, medial, lateral, and rotational[4].
  - Rotational dislocations are the rarest and are most commonly posteromedial
  - Frequently irreducible to closed reduction[5] due to interposition of soft tissues in the knee joint
    - Commonly medial structures such as the medial capsule, medial meniscus, or vastus medialis[6].
- This report describes a 15-year-old male with an irreducible, rotational, posterolateral knee dislocation due to incarceration of his avulsed medial collateral ligament
- This mechanism has not been previously described to the authors' knowledge

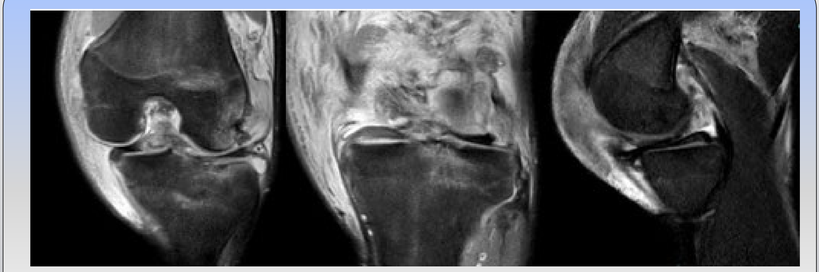

Figure 1: Two coronal and one sagittal T1-weighted MRI cuts demonstrating medial collateral ligament tear with posterior and lateral subluxation of the tibia relative to the femur.

The Case

- The patient is a 15-year-old male; presented to the ED with a left knee dislocation following a dirt bike accident.
- Initial presentation:
  - large effusion with knee locked in twenty degrees of flexion.
  - No open wound, neurologically intact
  - Puckering medially in the area of the MCL
  - 2+ dorsalis pedis and posterior tibial pulses; brisk capillary refill
  - Ankle-brachial index and CTA of the left lower extremity demonstrated low concern for vascular injury.
- Closed reduction was attempted, unsuccessfully.
- Patient placed into a long-leg splint in 20 degrees of flexion and transferred to a tertiary care center for ongoing management
- Patient remained neurovascularly intact on arrival to the tertiary care center, still with palpable DP and PT pulses and ankle-brachial index of greater than 0.9.
- Closed reduction was again attempted in the ED which demonstrated a mechanical block to full extension.
- Patient was re-splinted and sent for an MRI of the left knee to evaluate for ligamentous injuries and identify any mechanical blocks to reduction of the knee.

MRI findings (Figure 1):

- Complete tears of the anterior and posterior cruciate ligaments
- Tibial eminence avulsion fracture
- Complete tear of the medial collateral ligament
- Sprain of the lateral collateral ligament with some intact fibers
- Amorphous increased signal within the posterior horn of the medial meniscus concerning for complex tearing of the anterior and posterior root ligaments of the lateral meniscus
- Avulsion fracture of the lateral femoral condyle at the popliteus origin, and extensive soft tissue swelling with hemarthrosis

The Procedure

- Based on the MRI findings, the decision was made to proceed with operative intervention for the knee dislocation.
- Left knee was examined with fluoroscopy and found to still have medial widening and asymmetric reduction.
- Multiple manipulation attempts were made but the knee could not be symmetrically reduced.
- An 18-gauge needle was then used to perform an aspiration through a lateral subpatellar approach
  - 30cc of bloody fluid was aspirated.
- Manual reduction was again attempted, but the knee remained irreducible. Based on this, the decision was made to proceed with arthroscopy to evaluate what was blocking reduction.
- The knee was prepped and draped in the usual orthopedic sterile fashion. A standard arthroscopy was performed.
- Gravity only was used for water pressure to prevent significant extravasation.
- The patella and trochlea were then inspected and found to have no chondral injury.
- The medial compartment was very difficult to visualize due to the MCL being wrapped over the medial femoral condyle and into the medial compartment (Figure 2). A probe was then used to remove this, which was difficult, but accomplished.
  - The knee was then immediately clinically reduced.
- The medial compartment was then inspected, and no chondral injuries were seen (Figure 3). The meniscus was probed and intact. The notch was then inspected, and the ACL had an avulsion of the anterior tibial spine and intrasubstance fraying and the PCL appeared to be lax.
- The scope was passed laterally; the meniscus was intact, but the popliteus was not visible posteriorly. The chondral surface of the femur had a grade 1 injury that was debrided with a shaver. The tibial plateau was intact.
- Reduction was confirmed under fluoroscopy (Figure 4).
- The posterior tibial pulse was palpable with a faint dorsalis pedis pulse to doppler. The left lower extremity was then placed in a hinged knee brace in full extension.
- The patient was discharged on postoperative day one.

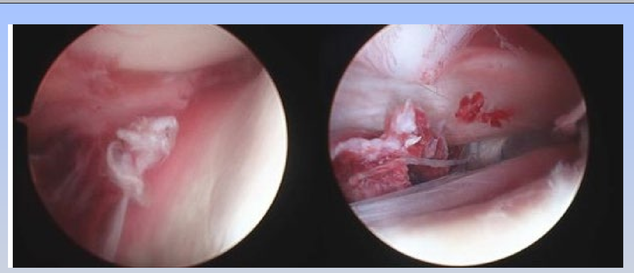

Figure 2: Arthroscopy pictures demonstrating torn MCL wrapped over medial femoral condyle and limiting visualization of the medial compartment.

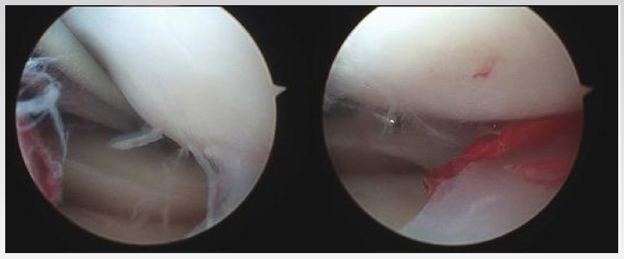

Figure 3: Arthroscopy pictures status post removal of the torn MCL from the intraarticular space, providing visualization of the medial compartment and demonstrating no chondral injuries.

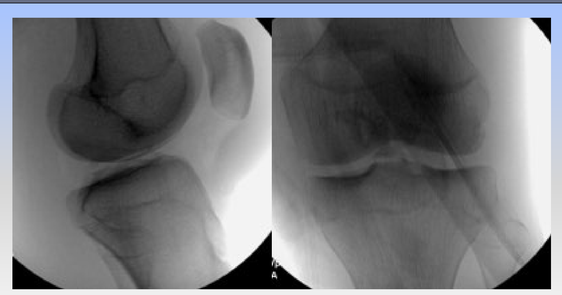

Figure 4: Post-reduction fluoroscopy pictures of the knee (Lateral on left, AP on the right) after reduction. Fracture of tibial eminence well-visualized on AP view.

Follow-up

- Ten days after initial presentation, the patient returned to the OR for definitive surgical management of his multi-ligamentous knee injury
- Underwent left knee PCL reconstruction and tibial spine avulsion (ACL avulsion) arthroscopic assisted reduction and internal fixation with open repair of the MCL
- At 2 weeks postoperatively, the patient was was weight-bearing as tolerated, locked in extension with flexion to 45 degrees in physical therapy only. Following expected course.
- At 4 weeks postoperatively, ROM was planned for incremental increase by 15 degrees per week.
- At 6 months postoperatively, the patient presented to clinic doing well and progressing with PT
  - ROM was 0-135° flexion; no extensor lag on straight leg raise.
  - Ligamentous testing:
    - 1A Lachman's with a 1-2 mm increase from the contralateral side;
    - 1A anterior and posterior drawer testing;
    - 1+ valgus laxity at 30 degrees flexion and negative in full extension.
  - Plan at that time was continued physical therapy working towards return to sport with follow-up at 9 months after surgery.

Discussion

- We present a case of a rare MCL avulsion off the medial femoral condyle causing a mechanical block to reduction after an acute traumatic knee dislocation
- Treated successfully with an arthroscopic assisted reduction and staged multi-ligament reconstruction.
- While, to the author's knowledge, there are no other known cases similar, this case represents a successful strategy to treat acute pediatric knee dislocations.
- While knee dislocations can have a wide variety of presentations, multi-ligamentous injuries, vascular injuries, associated fractures, and recurrent knee instability requiring external fixation for stabilization it is important to ensure the knee is concentrically reduced before determining plans for definitive fixation.

References

1. Lachman JR, Rehman S, Pipitone PS. Traumatic Knee Dislocations: Evaluation, Management, and Surgical Treatment. Orthop Clin North Am. 2015 Oct;46(4):479-93. doi: 10.1016/j.ocl.2015.06.004. Epub 2015 Aug 6. PMID: 26410637.
2. Peskun CJ, Levy BA, Fanelli GC, Stannard JP, Stuart MJ, MacDonald PB, Marx RG, Boyd JL, Whelan DB. Diagnosis and management of knee dislocations. Phys Sportsmed. 2010 Dec;38(4):101-11. doi: 10.3810/psm.2010.12.1832. PMID: 21150149.
3. Seroyer ST, Musahl V, Harner CD. Management of the acute knee dislocation: the Pittsburgh experience. Injury. 2008 Jul;39(7):710-8. doi: 10.1016/j.injury.2007.11.022. Epub 2008 May 12. PMID: 18472101.
4. Woon CY, Hutchinson MR. Posterolateral dislocation of the knee: Recognizing an uncommon entity. World J Orthop. 2016 Jun 18;7(6):401-5. doi: 10.5312/wjo.v7.i6.401. PMID: 27335816; PMCID: PMC4911524.
5. KENNEDY JC. COMPLETE DISLOCATION OF THE KNEE JOINT. J Bone Joint Surg Am. 1963 Jul;45:889-904. PMID: 14046474.
6. Rihn, J. , Cha, P. , Groff, Y. , Harner, C. & (2004). *Journal of the American Academy of Orthopaedic Surgeons, 12* (5), 334-346.