

Calcaneal (Heel) Fractures

DR. COURTNEY GRIMSRUD
CU ORTHOPEDICS - FOOT & ANKLE

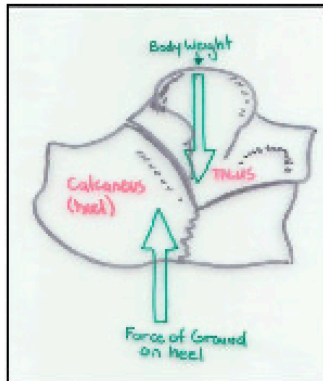


Figure 1: Side View
Mechanism of Injury

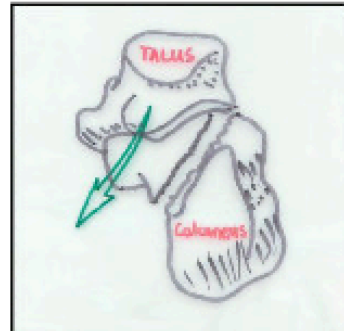


Figure 2:
View from Behind
Mechanism of Injury

How and What?

Fractures of the heel bone (calcaneus) can occur when significant loading or force is applied directly or indirectly to the heel bone. For example, a fall from a height landing on the heel, or a car crash where the heel is driven into the floorboard (See Figure 1&2).

The most common type of calcaneal fracture results in depression and crushing of the calcaneus. Think of the calcaneus as hard on the outside and soft on the inside like a funny shaped egg. The bone often breaks in a similar manner –into many small fragments. The fracture line can extend into the joint between the calcaneus and talus, called the “subtalar joint”. These issues can make fixing calcaneal fractures technically challenging. A depressed calcaneal fracture flattens and disrupts the important joint between the calcaneus and the talus (subtalar joint). This can lead to arthritis. Also, as the fractured heel bone is usually wider and shorter than before the injury this may cause rubbing of the tendons on the outside of the foot –and difficulty fitting into a shoe

Other types of calcaneal fractures (ex. “avulsion” and “chip” fractures) may occur. These “calcaneal” fractures involve smaller parts that do not connect to a joint surface, are less common, and may be easier to treat.

Symptoms

A depressed calcaneal fracture produces marked pain and swelling. Patients are usually unable to weight-bear through the heel because of the patient. Patients may develop fracture blisters due to the extensive swelling.

X-Rays and CT Scan

X-rays of the foot from the side will usually demonstrate the fracture. If surgery is contemplated it may be necessary to obtain a CT scan as this will give a more detailed view of the fracture pattern.

Treatment

Treatment of calcaneal fractures is controversial and both surgery and non-surgical treatment is often considered reasonable. Research studies suggest that outcomes can be similar regardless of treatment choice – but surgery seems to favor better outcomes in “low risk” patients and is less favorable in “high risk” patients. If surgery is performed it is important that a calcaneal fracture be fixed by a surgeon who is experienced and can discuss the risks and benefits of this type of surgery.

“Low-Risk” patients: young, female, non-smokers, non-worker’s compensation

“High-Risk” patients: older, male, smokers, diabetics, vascular disease, Workers compensation

Non-Operative Treatment

Rest, Ice, Elevation, Pain medication, Early motion, Non-weight-bearing for 8-12 weeks

Operative Treatment

Bone fragments are systematically reduced to their original position and then fixed with screws and plates (Figure 3). The subtalar joint is also reconstructed to its previous state. Post-surgery: Ice, elevate, pain medication, early motion, non-weight-bearing x 8-12 wks

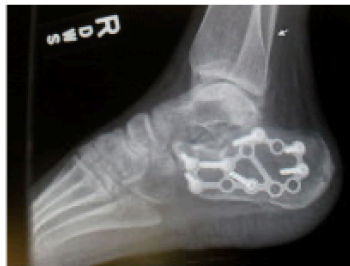

Figure 3:
Post surgery

Potential Complications of Surgery

Serious infection: The may even involve the bone due to the limited skin and soft-tissue covering the outside of the heel

Wound healing problems: The wound may breakdown leading to an infection.

Nerve Injury: The sural nerve runs past the outside part of the heel and can be injured.

Long-term hindfoot arthritis: The subtalar joint is often significantly injured. This may lead to some chronic hindfoot stiffness and pain and in some patients the subtalar joint may need to be fused.

The information contained in this handout is copyrighted by FootEducation LLC. It may be reproduced in small quantities for non commercial educational purposes. This information is for general education purposes only. It should not be used without guidance from a licensed healthcare provider. Edited By Ken Hunt MD, David Townshend MD, and Anthony Van Bergeyk MD