

Advances in the Management of Central Nervous System Infections in the ICU

Wendy C. Ziai, MD^{a,*},
John J. Lewin III, PharmD, BCPS^b

^a*Division of Neurosciences Critical Care, Departments of Neurology and Anesthesiology–Critical Care Medicine, The Johns Hopkins Medical Institutions, 600 North Wolfe Street, Baltimore, MD 21287, USA*

^b*Clinical Specialist, Neurosciences Critical Care, Departments of Pharmacy and Anesthesiology–Critical Care Medicine, The Johns Hopkins Medical Institutions, 600 North Wolfe Street, Baltimore, MD 21287, USA*

Central nervous system (CNS) infections presenting as meningitis, encephalitis, brain and epidural abscess, subdural empyema, and ventriculitis are encountered commonly in the ICU setting, and they are a significant cause of morbidity and mortality. Nosocomial CNS infections are a serious complication of neurosurgical interventions (craniotomy or ventriculostomy placement), craniocerebral trauma, and invasive neuromonitoring techniques. CNS infections may have acute and chronic neurological sequelae including seizures, hydrocephalus, focal neurological deficits, sensorineural hearing loss, cognitive deficits, and personality change [1]. Reducing morbidity and mortality is critically dependent on rapid diagnosis and on the initiation of appropriate antimicrobial therapy. Achievement of these goals remains a challenge because of logistical difficulties in providing timely antibiotic therapy, pharmacokinetic barriers to achieving effective concentrations of antimicrobials at the site of infection, and changing trends in microbial resistance. New insights into the role of inflammation and the immune response in CNS infections have contributed to development of new diagnostic strategies using markers of inflammation, and to the study of agents with focused immunomodulatory activity, which may lead to further adjunctive therapy in human disease.

* Corresponding author. Johns Hopkins Hospital, Division of Neurosciences Critical Care, 600 North Wolfe Street, Meyer 8-140, Baltimore, MD 21287, USA.

E-mail address: weziai@jhmi.edu (W.C. Ziai).

Anatomy and inflammation of the central nervous system

The ability of bacteria to enter between the pia (internal layer in direct contact with brain parenchyma) and arachnoid (middle layer) membranes delimiting the subarachnoid space is a multistep process requiring evasion of host defenses (Fig. 1). Bacteria responsible for meningitis attach to the nasopharyngeal epithelium, and are nearly all capable of secreting IgA proteases that prevent their destruction and allow them to traverse the epithelium and invade the intravascular space [2,3]. Interactions between the bacterial capsular polysaccharide coat and complement regulatory proteins protect pathogenic bacteria from the complement system, increasing their ability to cross the blood–brain barrier (BBB) and enter the cerebrospinal fluid (CSF) [4]. The BBB is a highly specialized structural and biochemical barrier that regulates the entry of molecules into the brain and maintains ionic homeostasis [5,6]. The BBB is composed of nonfenestrated capillaries whose endothelial cells form continuous tight junctions that seal the paracellular cleft between adjacent endothelial membranes and prevent passive diffusion from the intravascular space to the brain parenchyma [5]. Within the CNS, a relatively low concentration of immunoglobulin and weak complement-mediated host defenses enables bacterial replication. Endogenous inflammatory mediators such as interleukin (IL)-1, IL-6, and tumor necrosis factor (TNF)- α , which are part of the host immune response, are believed to contribute to neurological injury by stimulating migration of neutrophils into the CSF. These degranulate and cause increased permeability of the BBB, leading to vasogenic cerebral edema [7,8]. Stimulation of the host immune response depends on components of the bacterial cell wall and lipopolysaccharide surface proteins [8]. Because levels of

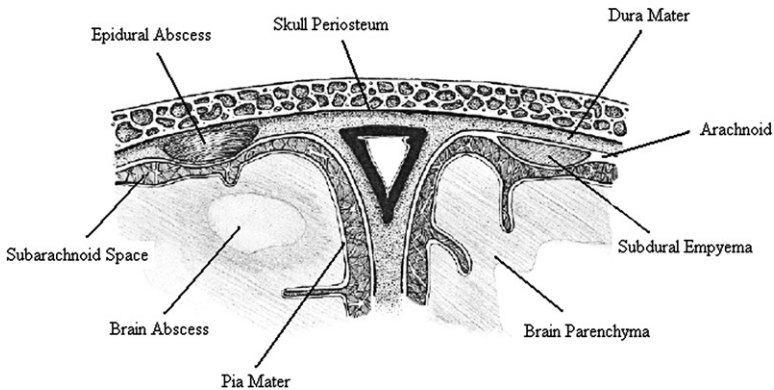


Fig. 1. Coronal view illustrating meningeal layers and common sites of central nervous system infections. (Reproduced from Lewin JJ, LaPointe M, Ziai WC. Central nervous system infections in the critically ill. *Journal of Pharmacy Practice* 2005;18(1):25–41; with permission.)

complements, immunoglobulins, and polymorphonuclear leukocytes are lower in the CSF than the serum, opsonic activity is inferior, mandating the use of bactericidal as opposed to bacteriostatic agents [9,10]. In meningitis/meningoencephalitis, proinflammatory cytokines (IL-1 α , IL-1 β , TNF α , IL-6, granulocyte macrophage colony-stimulating factor), produced by invading leukocytes, activated endothelial cells, astrocytes, and perivascular macrophages, regulate the extent of brain inflammation by altering brain endothelial cell junction complexes, thereby disrupting the BBB, resulting in local inflammatory responses and in the development of vasogenic brain edema [11–13]. Adhesion molecules (ICAM-1, VCAM-1) and selectins have been shown to alter tight junction complexes by regulating leukocyte/endothelial cell interactions, and leukocytes themselves increase vascular permeability through interactions with endothelial cells and release of proinflammatory mediators [14–16]. Finally, chemokines and chemoattractant cytokines such as IL-8, MCP-1, and CCL2 are proinflammatory mediators that selectively drive leukocytes into brain parenchyma and can regulate BBB permeability by means of expression of specific receptors on brain endothelial cells and by means of production of other proinflammatory agents [17].

Removing cytokine and chemokine activity with neutralizing antibodies to cytokines and chemokine receptor antagonists respectively has been shown experimentally to reduce brain edema formation. This may represent a new strategy for treating vasogenic brain edema, a significant factor producing morbidity in CNS infections [17–19]. Blockade of TNF α , which plays an important role in cochlear injury, reduced postmeningitic hearing loss and cochlear injury after *Streptococcus pneumoniae* meningitis [20]. Brain-derived neurotrophic factor (BDNF), which has marked antiapoptotic effects in hypoxic ischemic injury, has been shown to significantly reduce the extent of three forms of brain cell injury in an experimental meningitis model [21]:

- Cortical necrosis in group B streptococcal (GBS) meningitis
- Caspase-3-dependent cell death in *S pneumoniae* meningitis
- Caspase-3-independent hippocampal cell death in GBS meningitis

These therapies hold promise as adjunctive treatments for bacterial meningitis.

Also of importance is the blood–CSF barrier. The choroid plexi in the ventricles are perfused by unique fenestrated capillaries, with the barrier function here determined by tight junctions between ependymal cells separating these capillaries from the ventricular cavity. The BBB and blood–CSF barrier have different physiology, but they exert the same restraint on CNS drug distribution [22–24]. Altered permeability of these barriers during meningeal inflammation can increase drug penetration into the brain parenchyma and CSF with most antibiotics significantly, especially those that are poorly lipid-soluble [25].

Evaluating the patient with suspected central nervous system infection

The approach to a patient suspected to have a CNS infection begins with an evaluation of clinical features, which provides critical information leading to etiological diagnosis [26]. The identification of infectious agents in CNS infection remains highly dependent on the CSF analysis, and occasionally serum or biopsy data. Neuroimaging also plays a crucial role in diagnosis and therapeutic decision making.

Clinical presentation

Acute septic meningitis

This clinical condition constitutes a neurological emergency, and it is responsible for mortality and morbidity rates as high as 25% and 60%, respectively [27,28]. The classic triad of fever, neck stiffness, and altered mental status has a low sensitivity for diagnosis of bacterial meningitis. In a recent Dutch study of 696 episodes of adult community-acquired acute bacterial meningitis confirmed by CSF cultures, only 44% of cases had the full triad [29]. Ninety-five percent of episodes, however, had at least two of the four symptoms of headache, fever, neck stiffness, and altered mental status. On admission, 14% of patients were comatose, and 33% had focal neurological deficits. A retrospective French study investigated the accuracy of clinical presentation and relative diagnostic value of CSF parameters in distinguishing between bacterial and viral meningitis in 90 patients with confirmed bacterial meningitis and 54 patients with not previously treated viral meningitis [26]. Logistic regression analysis showed that the presence of severity (defined by one of four findings at admission: altered consciousness, seizures, focal neurological findings, and shock) and CSF absolute neutrophil count above 1000/mm³ were predictive of bacterial meningitis. CSF glucose less than 2 mmol/L and CSF protein above 2 g/L were not predictive.

Other caveats in the clinical diagnosis of meningitis are the potential lack of a febrile response in patients who are elderly, immunocompromised, or inadequately treated with antibiotics. Fever with altered mentation should alert the clinician to the possibility of meningitis in any elderly patient [30]. Nuchal rigidity (30%) and focal cranial nerve palsies including gaze paresis caused by hydrocephalus are not uncommon [31]. The occurrence of seizures, reported in 5% to 28% of meningitis cases, indicates cortical irritation, which may be caused by a cortically based complication (eg, empyema, stroke, or venous thrombosis) [32–34]. In a retrospective review of 103 episodes of acute bacterial meningitis in adults, seizure activity was an independent predictor of mortality (34% mortality in patients who had seizures compared with 7% without seizures; odds ratio 17.6, $P < .001$) [34]. Decreased level of consciousness on presentation was also predictive of death (26% versus 2%). Coma can be a consequence of fulminant bacterial meningitis with diffuse cerebral edema leading to cerebral herniation. Multiple cerebral infarcts secondary to vasculitis also have been described [35]. Other

manifestations of meningitis may provide clues to the causative organism: petechial or purpurial rash in meningococcal meningitis, ataxia and labyrinthitis in *Haemophilus influenzae* meningitis, and cough, weight loss, night sweats, and cranial nerve deficits in tuberculosis (TB) meningitis. Systemic complications have been reported in 22% of patients: septic shock in 12%, pneumonia in 8%, and disseminated intravascular coagulation in 8% [33]. In a multivariate analysis of 696 episodes of adult bacterial meningitis in the Netherlands treated between 1998 and 2002, risk factors for unfavorable outcome were:

- Advanced age
- Presence of osteitis or sinusitis
- Absence of rash
- Low admission Glasgow Coma Score (GCS) score
- Tachycardia
- Positive blood culture
- Elevated erythrocyte sedimentation rate
- Thrombocytopenia
- Low cerebrospinal fluid white cell count [29]

Encephalitis

Encephalitis is an acute infection of the brain parenchyma, and it most commonly is caused by viruses such as mumps, herpes simplex virus (HSV), cytomegalovirus (CMV), varicella zoster virus (VZV), enteroviruses, togaviruses (eastern and western equine viruses), and lymphocytic choriomeningitis virus (LCM). Recent developments in the epidemiology of viral encephalitis include the emergence of West Nile virus (WNV) and monkeypox in North America and Chandipura viruses (CHPV) in the developed world [36]. In addition, transmission of agents of viral encephalitis through blood transfusions and donated organs increasingly are recognized [36]. Encephalitis should be suspected in a febrile patient who presents with altered mental status or other signs of diffuse cerebral dysfunction. Clinical presentation often includes a prodrome with fever, headache, myalgia, and mild respiratory infection. Changes in level of consciousness with focal neurological deficits may follow. Seizures, both focal and generalized, are a common manifestation of the encephalitides. Specific viruses can have characteristic presentations, such as parotitis associated with mumps and herpetic rash with herpes simplex encephalitis (HSE). Diplopia, dysarthria, and ataxia can be seen in immunocompromised patients with brainstem HSE [37,38].

HSE is the most important form of treatable encephalitis. It has a predilection for the temporal and orbitofrontal lobes, and results in a clinical picture of altered consciousness, memory loss, personality change, and confusion or olfactory hallucinations, following a prodrome of headache and fever [39]. HSE is a medical emergency, and it is associated with a high mortality rate and numerous sequelae such as cognitive and behavioral disorders, and seizures and postinfectious encephalomyelitis [40,41].

WNV encephalitis, usually affecting persons over age 55, has a 15% mortality rate [42,43]. Neuroinvasive WNV occurs in approximately 1% to 2% of infections [36]. Neurological features include movement disorders sometimes with parkinsonian features, postural tremor, and myoclonus and cerebellar signs [44–46]. In its most severe form, WNV can cause acute flaccid limb paralysis caused by infection of the anterior horn cells of the spinal cord causing profound weakness akin to poliovirus infection [47]. This manifestation, referred to as poliomyelitis-like illness, affects 10% of cases with neuroinvasive disease and also occurs in other flavivirus encephalitides (Japanese encephalitis virus and St. Louis encephalitis virus) and enteroviruses [45,48]. The mortality in WNV is caused by respiratory failure 50% of the time; morbidity is also high because of long-term limb weakness and functional disability [47]. Other findings associated with WNV are ophthalmologic disease such as chorioretinitis and vitritis and rhabdomyolysis [49,50]. Pediatric WNV infection rates are similar to adults and accounted for 12% of all neuroinvasive cases in the United States in 2004 [51]. Manifestations of neuroinvasive WNV in children are similar to adults [52].

Brain abscess

Brain abscesses are focal, purulent infections of brain parenchyma. They commonly present with site-specific focal neurological deficits such as aphasia and weakness. A focal examination may, however, be absent, and signs of increased intracranial pressure may be the only presenting feature [53]. Fever is less common than in meningitis. Neck rigidity may be present in 25% of cases and may indicate associated meningitis [30]. Seizures, often generalized tonic–clonic, occur in up to 40% of cases [54].

Cranial epidural abscess

Cranial epidural abscess is an extra-axial infection occurring in the virtual space between the dura mater and the skull. It usually occurs in the frontal region, and it can present with headache, fever, and nausea. Neurological symptoms and complications are quite rare, as the dura mater provides protection to the brain parenchyma, and tight adherence of dura to the overlying skull limits the spread. These infections typically occur as a result of trauma and neurosurgery, but other sources such as meningitis, sinusitis, and other extra-cranial sources have been implicated. The most common infectious etiologies include streptococci, staphylococci, and anaerobes, and infections are often polymicrobial [55,56].

Subdural empyema

Subdural empyema is an infection that occurs in the potential space between the dura mater and the arachnoid. It is most commonly situated over the cerebral convexity, and it can cause an altered level of consciousness, focal neurological deficits, and seizures. Unlike the epidural space, the subdural space is less restrictive, resulting in a wider spread of empyema, which

can cause inflammation of the brain parenchyma, edema, mass effect, elevated ICP, septic thrombophlebitis, and venous infarction [55,57]. Subdural empyema is associated with a much more complicated course, and worse outcome, than epidural abscess. Sources of infection include the para-nasal sinuses, hematogenous spread by means of emissary veins located in the subdural space, and in the postoperative setting extension of an epidural abscess into the subdural space [55,58].

Ventriculitis

Ventriculitis is an infection of the ventricular system of the brain. The ventricles can act as a reservoir of infection and inflammation, resulting in blockade of CSF outflow tracts and hydrocephalus [59]. Ventriculitis occurs as a complication of meningitis in 30% of adult cases, and as many as 90% of neonatal cases [57]. It is clinically relevant when inflammation and bacterial load in the ventricles are significantly higher than in the paraspinal space [60]. It often is thought to be a late complication of meningitis indicated by failure to improve with conventional therapy for meningitis, but it can occur as a primary process [60,61]. In addition, it frequently is associated with the presence of a CSF shunt, external ventricular drain (EVD), or other intracranial device. The risk of developing a ventriculitis or meningitis with an EVD in place is reported to be as high as 45%, but more commonly it is reported in the 10% to 15% range, and it depends on the type of EVD, insertion technique, management, and length of time the EVD is in place [62–65]. Hemorrhagic CSF is a risk factor for ventriculostomy-related infections, and hemorrhagic CSF likely contributes to the 10% incidence of such infections in aneurysmal subarachnoid hemorrhage patients who have EVDs, and the 13.7% incidence after intraventricular hemorrhage [64,66]. A protocol of meticulous EVD care has been shown to prolong EVD use and minimize infection rates [67]. Protocol violations and CSF leaks were significant risk factors for infection in this study. Infection has been reported in 8% to 40% of patients receiving a CSF shunt, with most infections occurring within 1 month of implantation [55].

The most common pathogens involved in EVD and CSF shunt infections are gram-positive organisms such as *Staphylococcus epidermidis* and *Staphylococcus aureus*. As many as 25% of infections, however, are caused by gram-negative organisms such as *Escherichia coli*, *Klebsiella* species, *Acinetobacter*, and *Pseudomonas* species. These organisms should be suspected in patients with a ventriculoperitoneal shunt, as a result of contamination of the peritoneal end of the catheter [55].

Cerebrospinal fluid analysis

CSF analysis is the cornerstone of diagnosis and management of CNS infection. The two major issues that may interfere with appropriate and timely

CSF analysis (either by lumbar puncture [LP] or shunt tap) are concerns about uncocal or cerebellar tonsillar herniation and the need to initiate empiric antibiotics emergently. The availability of CT frequently delays starting antimicrobial therapy [68]. In van de Beek's study, CT was performed before LP in 48% of patients, and in 63% of those presenting with moderate or severely impaired consciousness or neurological deficits [29]. In two thirds of patients who had a CT scan, antimicrobial therapy was not started until after CT results were obtained. It has become common practice to perform CT of the head before performing LP in patients suspected of meningitis, owing to a perception that this is standard of care or because of litigation [69].

In a prospective study of 301 adults with clinically suspected meningitis, Hasbun and colleagues sought to determine whether clinical characteristics could identify patients who were unlikely to have abnormalities on CT [69]. Of 78% of patients who underwent CT before LP, 24% had an abnormal finding, and 5% had a mass effect. Abnormal findings on CT were associated with the following clinical features at baseline:

- Age greater than 60 years
- Immunocompromised state
- History of a CNS lesion
- History of seizures within 1 week before presentation
- Abnormal level of consciousness
- Inability to answer two consecutive questions correctly or follow two consecutive commands
- Gaze palsy
- Abnormal visual fields
- Facial palsy
- Arm drift
- Leg drift
- Abnormal language

Of the 96 patients who had none of these findings, only three had abnormal findings on CT, yielding a negative predictive value of 97%. These three patients underwent LP without subsequent herniation. There was a significant delay from admission to time of lumbar puncture in patients who first underwent CT, and a trend toward greater delay in administering empiric antibiotic therapy in the group undergoing head CT first [69]. These data and other data support a strategy of obtaining a head CT before lumbar puncture only in patients who have clinical features that increase the likelihood of an intracranial mass lesion or elevated intracranial pressure [70]. These include:

- Immunosuppression (to rule out *Toxoplasma* encephalitis or lymphoma)
- Significant alteration in mentation or comatose patient
- Focal neurological deficits
- Seizures

- Papilledema, poorly reactive pupils, or ocular palsies
- Bradycardia or irregular respirations
- Sedation or muscle paralysis [71]

Even without abnormalities on CT, clinical signs suggestive of increased ICP should caution against use of LP, or suggest use of a 22 or 25 gauge needle to remove the smallest amount of CSF possible and minimize leakage of CSF [70]. Patients identified as high risk should have blood drawn for culture and empiric antibiotic therapy initiated before undergoing CT. Delaying antibiotic treatment by even a few hours has been associated with adverse outcomes in patients with bacterial meningitis, although rigorous studies are lacking [72]. The diagnostic sensitivity of the CSF will not be diminished by delaying the LP by 1 or 2 hours after initiating antibiotic therapy [73]. CSF counterimmunoelectrophoresis, CSF latex agglutination, and coagulation tests can detect common bacterial antigens in 70% to 100% of patients.

CSF findings in various CNS infections are presented in Table 1. In bacterial meningitis, CSF Gram's stain will indicate organisms in 60% to 90% of cases and positive cultures in 80% of cases [30]. Ninety percent of patients will have a CSF cell count greater than 100 white blood cell count (WBC)/mm³, and about 60% have cell counts greater than 1000 WBC/mm²³ [74]. CSF glucose levels are less than 40 mg/dL in 50% to 60% of patients; using a CSF to serum glucose ratio of no more than 0.4 is 80% sensitive and 98% specific in children older than 2 months of age [75]. CSF glucose also

Table 1
Cerebrospinal fluid findings in central nervous system infections

	Cell count (cells/mm ³)	Glucose	Protein
Bacterial meningitis	Elevated (100–5000) PMNs predominate	Decreased	Elevated
Viral meningitis	Elevated (10–500) Lymphocytes predominate	Normal	Elevated
Fungal meningitis	Normal to elevated (0–500) Lymphocytes predominate	Normal to decreased	Elevated
Tuberculous meningitis	Normal to elevated (0–1000) Lymphocytes predominate	Decreased	Elevated
Brain abscess	Normal to elevated (0–500) Mixed differential	Normal	Elevated
Ventriculitis	Elevated (100–5000)* PMNs predominate	Decreased	Elevated

Abbreviation: PMNs, Polymorphonuclear leukocytes.

* In postneurosurgical patients or patients with a ventriculostomy, the cerebrospinal fluid (CSF) cell count may be elevated as a result of surgical manipulation and inflammation. Reduction in CSF glucose may be a more sensitive indicator of infection.

Data from Lewin JJ, LaPointe M, Ziai WC. Central nervous system infections in the critically ill. *Journal of Pharmacy Practice* 2005;18(1):25–41.

may be reduced in fungal, tuberculous, or carcinomatous meningitis. Partial antibiotic treatment may alter the CSF characteristics. The CSF protein level is the most resistant to rapid change, with treatment remaining elevated for 10 days or more [74]. The CSF findings in the case of subdural empyema and epidural abscess (if an LP is performed) typically consist of a polymorphonuclear pleocytosis (10 to 500 WBC/mm³), normal glucose, increased protein, and often negative Gram's stain and culture [54]. Blood cultures in the presence of meningitis are positive in up to 50% of cases, and a touch preparation of the rash in meningococcal meningitis yields a positive Gram's stain in 70% of cases [55].

Measurement of CSF lactate concentrations is not recommended for suspected community-acquired bacterial meningitis, because it is generally nonspecific and provides little additional diagnostic information [75]. In postoperative neurosurgical patients, however, a CSF lactate concentration cut-off of 4 mmol/L was found to be superior to the CSF to serum glucose ratio for diagnosis of bacterial meningitis [76]. The sensitivity was 88%, and specificity was 98%. The positive predictive value was 96%; negative predictive value was 94%.

Latex agglutination tests for bacterial antigens are positive in 50% to 100% of cases depending on the organism. Routine use has been questioned, however, because bacterial antigen testing does not appear to modify the decision to administer antimicrobials. Additionally, false-positive results have been reported [75]. Hence they are not recommended for managing bacterial meningitis, but they may be useful for patients pretreated with antibiotics with negative Gram's stain and CSF cultures [75]. Bacterial DNA detection by polymerase chain reaction (PCR) for common meningeal pathogens is available and undergoing further refinements [75]. Broad-range real-time PCR and DNA sequencing for diagnosis of bacterial meningitis allows detection of virtually all pathogenic bacteria and has been shown to have a sensitivity of 86% to 100% and specificity of 98% when compared with culture [77,78]. Although availability is limited, broad-range real-time PCR makes diagnosis before culture results possible, and this may be a useful supplement for influencing decisions to initiate or discontinue antibiotics, particularly in previously treated patients [77].

The acid-fast stain for TB has sensitivity as low as 30%; however, repeat CSF sampling can improve sensitivity to 80% [55]. Molecular diagnosis with commercial nucleic acid amplification assays for diagnosis of TB meningitis has a sensitivity of 56% and specificity of 98% based on a meta-analysis [79]. Currently, careful bacteriology is as good as or better than molecular methods, although the latter are sensitive for longer when anti-TB drugs have been started [80].

Several acute-phase reactants have been examined for their usefulness in diagnosing acute bacterial meningitis, including C-reactive protein (CRP) and serum procalcitonin (PCT). CRP measurement may be useful in patients who have CSF findings consistent with meningitis, but negative

Gram's stain where the clinician may consider withholding antimicrobial therapy based on the high negative predictive value of a normal CRP in bacterial meningitis (99%) compared with viral meningitis in children (class II-B evidence) [75,81]. Elevated PCT concentrations have been shown to be useful in differentiating between bacterial and viral meningitis in children (cut-off > 5.0 µg/L; sensitivity 94%; specificity 100%) and adults (cut-off > .2 ng/mL; sensitivity and specificity up to 100%) [82–84]. PCT levels were studied in 50 adults with community-acquired acute bacterial meningitis and no other infection or prior antibiotics [85]. Of 48 patients with a serum PCT level on admission above 0.5 ng/mL, median serum PCT levels on admission and on day 2 were 4.5 and 2 mg/mL, respectively ($P < .0001$), compared with median CRP levels of 120 and 156, respectively. Serum PCT levels decreased rapidly (within 24 hours) with appropriate antibiotic treatment, suggesting this test may be valuable in assessing the efficacy of antibiotic therapy and potentially replacing repeat lumbar puncture at 48 to 72 hours [85]. Alternatively, in patients with ventriculitis and a ventricular catheter, PCT levels usually remain within the normal range, even with positive bacterial cultures. Thus levels do not assist with diagnosis as they do when differentiating between viral and bacterial meningitis [86,87].

Patients who have CNS viral infection may demonstrate normal-to-mild elevation of ICP, CSF lymphocytosis, WBC counts of 50 to 2000/mm³, normal glucose, and elevated protein [54]. CSF culture and serological testing of acute and convalescent serum may be beneficial. For HSE, PCR in CSF has a sensitivity and specificity of 98% and 94%, respectively. One third of cases remain PCR-positive long after starting acyclovir treatment [88]. PCR has good specificity for cytomegalovirus (95%) and *Toxoplasma* (100%), but lower sensitivity (79% and 42%, respectively) [54]. In patients with suspected enteroviral meningitis, enteroviral RT-PCR has been found to be more sensitive than viral culture for detecting enteroviruses (sensitivity 86% to 100%; specificity 92% to 100%) [89]. The diagnosis of some viruses is determined by detection of IgM antibodies by an ELISA.

In severely immunosuppressed patients with fungal meningitis, CSF may appear normal, while opening pressure may be high. In cryptococcal meningitis in patients who have HIV, a predominantly lymphocytic pleocytosis with low CSF glucose and high protein levels is common [31]. The encapsulated fungus can be identified by India ink examination of CSF, and serologic detection of cryptococcal antigen is sensitive and relatively specific for CNS cryptococcal infection.

In patients who improve with antimicrobial therapy, repeat lumbar puncture and CSF analysis to document CSF sterilization is not indicated routinely [75]. Patients who have not responded clinically after 48 hours of appropriate antimicrobial therapy, especially those who have penicillin- or cephalosporin-resistant pneumococcal meningitis, and those who are on adjunctive dexamethasone therapy, should undergo repeat CSF analysis [75,90].

Neuroimaging of central nervous system infections

In uncomplicated bacterial meningitis, CT scans are usually sufficient for clinical management to exclude cerebral edema, hydrocephalus, and base of skull pathology (eg, fractures, inner ear infection, or mastoiditis). Other findings include subdural effusions, brain stem encephalitis (rhombencephalitis) with *Listeria* infection, and cortical infarcts secondary to vasculitis in up to 20% of cases [91]. CT or MR venography should be considered to diagnose complicating cerebral venous sinus thrombosis.

MR diffusion-weighted imaging (DWI) shows parenchymal complications of meningitis such as infarcts of septic vasculitis earlier than other sequences. Encephalitis, cerebritis, and TB are DWI-hyperintense; neurocysticercosis lesions are DWI-hypointense. Toxoplasmosis is variable, whereas lymphoma shows no restriction of water diffusion [91]. MR angiography can suggest vasculitis. Ventriculitis is detected best by T2 fluid-attenuated inversion recovery (FLAIR) images showing periventricular hyperintensity on ependymal enhancement and irregular intraventricular debris [91].

In TB meningitis, basal enhancement, hydrocephalus, tuberculoma, and infarction are all more common than in pyogenic meningitis, in which subdural collections are more common [92]. Based on a CT study of 94 children with TB meningitis, Kumar and colleagues [92] found that basal meningeal enhancement or tuberculoma was 89% sensitive and 100% specific for diagnosis of TB. Precontrast hyperdensity in the basal cisterns on cranial MRI may be the most specific radiological sign of TB meningitis in children [93]. In Lyme disease, multifocal nonenhancing patchy lesions on T2 weighted images can be seen [91].

In cases of acute HSV encephalitis, FLAIR or T2 weighted sequences showing asymmetrical changes of necrotizing encephalitis in the first 48 hours may be diagnostic. Diffusion abnormalities disappear within 14 days after symptom onset, while T2 hyperintensities persist [91]. Single photon emission CT (SPECT) may indicate hyperperfusion suggestive of inflammation and neuronal injury in the temporal and frontal lobes relatively early, although half of scans are normal in the acute stage, and hyperperfusion is a nonspecific finding [54].

Pyogenic abscesses are hyperintense on DWI with reduced apparent diffusion coefficient (ADC) in contrast to nonpyogenic lesions, which are generally hypointense or mixed-signal. Proton MR spectroscopy (PMRS) showing lactate, cytosolic amino acids, and absence of choline suggests abscess [91]. Extra-axial bacterial empyemas appear slightly hyperintense relative to CSF and hypointense to white matter on T1WI and hyperintense on T2WI, distinguishing them from sterile effusions and chronic hematomas [91]. Epidural hematomas can be distinguished from subdural empyema by a hypointense rim representing displaced dura. On DWI, subdural empyema is usually hyperintense, whereas epidural hematoma usually has a low or mixed-signal intensity [91].

Antimicrobial therapy

Distribution of drug into the central nervous system

Antimicrobial distribution into the CNS is influenced by not only physical barriers, but also by the inherent physiochemical properties of the antimicrobial itself. The major physiochemical factors governing antimicrobial penetration of the CNS are listed in Table 2. Because only the unbound concentration of drug is available for diffusion across the BBB and blood–CSF barrier, highly protein-bound agents have limited ability to penetrate the CNS [94]. The tight junctions within the BBB and blood–CSF barrier limit diffusion of large molecular weight substances (> 500 d). Anti-infectives with larger molecular weights (eg, vancomycin or amphotericin B) have limited ability to penetrate an intact barrier [22,94].

Other factors being held constant, more lipophilic agents (as characterized by a high octanol:water partition coefficient) will penetrate the CNS more readily than hydrophilic compounds. Lipophilicity also can affect the distribution of drugs within the CNS. Highly lipophilic agents accumulate in the lipid-rich brain structures, with a resultant lower concentration in the CSF and extracellular fluid (ECF) and potential underestimation of overall CNS penetration when CSF levels are measured [94]. The degree of ionization at physiologic pH also may have an effect on penetration of the BBB. Because most drugs are weak acids or weak bases, polarity can vary depending on the pH. Because the pH of blood, CSF, and ECF can change with infection, this can influence the polarity and hence anti-infective penetration of the CNS [94].

The choroid plexus contains specialized active transcellular transport systems involved in the excretion of drugs across the cerebral vessel wall [22]. During active CNS infection, impaired CSF excretion systems may result in higher CSF concentrations of antibiotics. As inflammation diminishes, antibiotic concentrations can decrease accordingly [23].

Table 2
Physiochemical properties influencing antimicrobial penetration into the central nervous system

Physiochemical property	Effect on central nervous system penetration
Lipophilicity	Highly lipophilic drugs more readily penetrate the CNS
Protein binding	Highly protein-bound drugs have reduced CNS penetration
Molecular weight	Substances >500–800 d have reduced ability to penetrate the BBB
Ionization	Polar, ionized compounds are less likely to cross the BBB. Polarity can vary for many drugs with changes in physiologic pH
Active transport	Specialized active transport cells in the choroid plexus may excrete drugs across the vessel wall

Abbreviations: BBB, blood–brain barrier; CNS, central nervous system.

Data from Refs. [2–4].

Timing and appropriateness of initial antimicrobial therapy

Delayed or inappropriate initial antibiotic therapy has been associated with increased mortality or morbidity for numerous infectious diseases, including: community-acquired pneumonia [95], ventilator-associated pneumonia [96], and sepsis [97,98]. A similar observation was noted for infections of the CNS in a retrospective cohort study of 269 patients with bacterial meningitis and risk factors for adverse outcomes (worsening mental status, hypotension, or seizures), which suggested that early antibiotic therapy can prevent early clinical deterioration and is associated with a reduction in mortality or adverse neurological sequelae [72]. The appropriate selection of initial antibiotics is also crucial. In a retrospective review of 109 patients with community-acquired meningitis, 22 patients did not receive appropriate initial antibiotic coverage, of whom 100% died, as compared with 23% of patients receiving appropriate therapy ($P < .001$) [99].

Antimicrobial selection and dosing

Meningitis

Empiric therapy of meningitis needs to consider the most likely organisms involved, which in turn depend on patient age, immune status, and whether the infection is acquired in the community or nosocomial setting. Recommendations for empiric therapy of meningitis based on patient-specific factors are listed in Table 3. Organism-specific recommendations are provided in Table 4.

Haemophilus influenzae accounted for nearly 50% of bacterial meningitis cases (most being in children) before the availability and widespread use of the *H influenzae* type B vaccine [1,100]. Now *H influenzae* causes only a small percentage of cases, with the median age of patients with bacterial meningitis shifting from 15 months to 25 years [101]. A 1995 survey performed after the institution of the vaccine indicated that most cases (47%) of community-acquired bacterial meningitis were caused by *Streptococcus pneumoniae*, followed by *Neisseria meningitidis* (25%), Group B streptococcus (13%), *Listeria monocytogenes* (8%), and *H influenzae* (7%) [101]. More recent reports point to the growing importance of traditionally nosocomial gram-negative organisms (eg, *Klebsiella* species, *Serratia* species, *Pseudomonas* species, and *Acinetobacter* species) [102]. Such trends reflect a shift in the epidemiology of meningitis from a disease of the young and otherwise healthy to a disease of the elderly and immunocompromised. The immunocompromised are susceptible to meningitis caused by *Listeria monocytogenes* and gram-negative bacilli such as those listed previously, in addition to commonly encountered organisms such as *S pneumoniae*.

Empiric therapy of meningitis occurring in the setting of neurosurgery, head trauma/CSF leak, and cerebrospinal shunts warrants special consideration. The most common organisms are *S aureus* and gram-negative bacilli. Effective source control is critical, which often necessitates surgical removal

of foreign materials. In patients with CSF shunts who are shunt-dependent, removal of the shunt often necessitates placement of a temporary EVD.

For TB meningitis, the Infectious Diseases Society of America and American Thoracic Society recommend a similar regimen as for pulmonary TB [103]. This involves an intensive 2-month phase with four drugs (isoniazid, rifampin, pyrazinamide, and ethambutol) followed by a continuation phase for 6 to 9 months.

Ventriculitis and cerebrospinal fluid shunt infections

Initial antibiotic selection should be broad and include coverage for resistant gram-positive organisms (such as MRSA) and resistant gram-negative organisms (such as *Pseudomonas* and *Acinetobacter* species). Vancomycin in association with a cephalosporin with antipseudomonal activity (eg, cefepime or ceftazidime), or vancomycin plus meropenem is recommended. In addition to antimicrobial therapy, any infected hardware should be removed, replaced, or externalized when appropriate.

The presence of inflammation in the setting of bacterial meningitis enhances the ability of a given antimicrobial to penetrate the BBB; however, meningeal inflammation may be less pronounced in ventriculitis [104]. In addition, the ventricles can act as a persistent reservoir of infection and inflammation, resulting in extreme difficulty in eradicating infection and potential blockade of CSF outflow tracts [59]. These characteristics illustrate the challenges of treating ventriculitis and suggest why treatment failures are common. Intraventricular and intrathecal administration of antibiotics has been advocated in an effort to overcome these difficulties in selected cases [105,106].

Brain abscess

The type of pathogen associated with brain abscess varies depending on patient-specific risk factors. Immunocompromised patients and patients undergoing recent neurosurgery or head trauma (especially penetrating brain injury) are at higher risk [107,108]. Brain abscesses are often polymicrobial in nature (up to 60% of cases), with anaerobic bacteria implicated in up to 49% of cases [109,110]. Organisms frequently isolated include: *Streptococcus milleri*, *Bacteroides* species, *Enterobacteriaceae*, and *S aureus*. In addition, immunocompromised individuals are at risk for brain abscess from fungi, *Nocardia*, and *Toxoplasma*.

As with other deep-seated infections, optimal treatment involves a combination of antibiotics and surgical intervention to obtain source control. Surgical approaches include stereotactic aspiration or excision of the abscess. Stereotactic aspiration may be preferred if the abscess develops in eloquent areas of the brain unsuitable for excision (eg, brainstem or diencephalic structures) [111]. Given the polymicrobial nature of brain abscess, broad-spectrum empiric therapy is indicated, the choice of which depends largely on risk factors for selected organisms (history, immune status, primary

Table 3
 Recommendations for empiric antimicrobial therapy for bacterial meningitis in adults

Patient-specific factor	Common pathogens	Preferred regimen	Alternative regimens
18–50 years	<i>Streptococcus pneumoniae</i> , <i>Neisseria meningitides</i> , <i>Haemophilus influenzae</i> (non-immunized patients)	Ceftriaxone ⁵ 2 g intravenously every 12 h or Cefotaxime ¹ 2 g intravenously every 6 h plus Vancomycin ^{1,2} 15 mg/kg intravenously every 8–12 h	Meropenem ¹ 2 g intravenously every 8 h or Chloramphenicol ^{3,4} 50–100 mg/kg/d in 4 divided doses or Moxifloxacin ³ 400 mg/d intravenously plus Vancomycin ^{1,2} 15 mg/kg intravenously every 8–12 h
> 50 years	<i>S pneumoniae</i> , <i>N meningitides</i> , <i>Listeria monocytogenes</i> , gram-negative bacilli	Ampicillin ¹ , 2 intravenously every 4 h plus Vancomycin ^{1,2} 15 mg/kg intravenously every 8–12 h plus Ceftriaxone ⁵ 2 g intravenously every 12 h or Cefotaxime ¹ 2 g intravenously every 6 h	Ampicillin ¹ 2 g intravenously every 4 h or Trimethoprim/sulfamethoxazole ¹ 5 mg/kg (TMP) intravenously every 6 h plus Vancomycin ^{1,2} 15 mg/kg intravenously every 8–12 h plus Meropenem ¹ 2 g intravenously every 8 h or Moxifloxacin ³ 400 mg/d intravenously

Impaired immunity	<i>L monocytogenes</i> , gram-negative bacilli, <i>S pneumoniae</i> , <i>N meningitides</i>	Ampicillin ¹ 2 g intravenously every 4 h plus Vancomycin ^{1,2} 15 mg/kg intravenously every 8–12 h plus Ceftazidime ¹ 2 g intravenously every 8 h or Cefepime ¹ 2 g intravenously every 8 h	Ampicillin ¹ 2 g intravenously every 4 h or Trimethoprim/sulfamethoxazole ¹ 5 mg/kg (TMP) intravenously every 6 h plus Vancomycin ^{1,2} 15 mg/kg intravenously every 8–12 h plus Meropenem ¹ 2 g intravenously every 8 h or Ciprofloxacin ¹ 400 mg intravenously every 8 h
Neurosurgery, head trauma, CSF shunt	Staphylococci, gram-negative bacilli, <i>S pneumoniae</i>	Vancomycin ^{1,2} 15 mg/kg intravenously every 8–12 h plus Cefepime ¹ 2 g intravenously every 8 h or Ceftazidime ¹ 2 g intravenously every 8 h	Vancomycin ^{1,2} 15 mg/kg intravenously every 8–12 h plus Meropenem ¹ 2 g intravenously every 8 h or Ciprofloxacin ¹ 400 mg intravenously every 8 h

¹ Dose adjust for renal insufficiency.

² Monitoring of serum drug levels is recommended to optimize dosing.

³ Caution in patients with hepatic insufficiency; dose adjustment may be required.

⁴ Monitor for bone marrow suppression, including leukopenia, thrombocytopenia, and aplastic anemia.

⁵ Dose adjustments may be indicated in patients with combined hepatic and renal insufficiency.

Data from Lewin JJ, LaPointe M, Ziai WC. Central nervous system infections in the critically ill. *Journal of Pharmacy Practice* 2005;18(1):25–41.

Table 4

Pathogen-specific recommendations for antimicrobial therapy for bacterial meningitis in adults

Organism	Preferred regimen	Alternative regimen	Duration
<i>Streptococcus pneumoniae</i> (PCN MIC < 0.1)	Penicillin G ¹ 4 million units intravenously every 4 h or Ceftriaxone ⁵ 2 g intravenously every 12 h or Cefotaxime ¹ 2 g intravenously every 6 h	Meropenem ¹ 2 g intravenously every 8 h or Chloramphenicol ^{3,4} 50–100 mg/kg/d in 4 divided doses or Moxifloxacin ³ 400 mg/d intravenously	10–14 days
<i>S pneumoniae</i> (PCN MIC ≥ 0.1) (CTX MIC ≤ 0.5)	Ceftriaxone ⁵ 2 g intravenously every 12 h or Cefotaxime ¹ 2 g intravenously every 6 h	Meropenem ¹ 2 g intravenously every 8 h or Moxifloxacin ³ 400 mg/d intravenously or Vancomycin ^{1,2} 15 mg/kg intravenously every 8–12 h	10–14 days
<i>S pneumoniae</i> (PCN MIC ≥ 0.1) (CTX MIC > 0.5)	Vancomycin ^{1,2} 15 mg/kg intravenously every 8–12 h plus Ceftriaxone ⁵ 2 g intravenously every 12 h or Cefotaxime ¹ 2 g intravenously every 6 h	Vancomycin ^{1,2} 15 mg/kg intravenously every 8–12 h plus Rifampin ³ 900–1200 mg/d intravenously or by mouth in 2–3 divided doses	10–14 days
<i>N meningitidis</i>	Penicillin G ¹ 4 million units intravenously every 4 h	Ampicillin ¹ 2 g intravenously every 4 h or Ceftriaxone ⁵ 2 g intravenously every 12 h or Cefotaxime ¹ 2 g intravenously every 6 h or Chloramphenicol ^{3,4} 50–100 mg/kg/d in 4 divided doses	7–10 days

<i>Haemophilus influenzae</i>	Ceftriaxone ⁵ 2 g intravenously every 12 h or Cefotaxime ¹ 2 g intravenously every 6 h	Chloramphenicol ^{3,4} 50–100 mg/kg/d in 4 divided doses	7–10 days
<i>L monocytogenes</i>	Ampicillin ¹ 2 g intravenously every 4 h plus Gentamicin ^{1,2,6} 3–5 mg/kg/d intravenously in 3 divided doses	Trimethoprim/sulfamethoxazole ¹ 5 mg/kg (TMP) intravenously every 6 h	21 days
Group B streptococcus	Penicillin G ¹ 4 million units intravenously every 4 h or Ampicillin ¹ 2 g intravenously every 4 h	Vancomycin ^{1,2} 15 mg/kg intravenously every 8–12 h or Ceftriaxone ⁵ 2 g intravenously every 12 h or Cefotaxime ¹ 2 g intravenously every 6 h	14–21 days
<i>Enterobacteriaceae, Klebsiella</i> species	Ceftriaxone ⁵ 2 g intravenously every 12 h or Cefotaxime ¹ 2 g intravenously every 6 h +/- Gentamicin ^{1,2,6} 3–5 mg/kg/d intravenously in 3 divided doses or Ciprofloxacin ¹ 400 mg intravenously every 8 h	Meropenem ¹ 2 g intravenously every 8 h +/- Gentamicin ^{1,2,6} 3–5 mg/kg/d intravenously in 3 divided doses or Ciprofloxacin ¹ 400 mg intravenously every 8 h	14–21 days

(continued on next page)

Table 4 (continued)

Organism	Preferred regimen	Alternative regimen	Duration
<i>Pseudomonas aeruginosa</i> , <i>Acinetobacter</i> species	Cefepime ¹ 2 g intravenously every 8 h or Ceftazidime ¹ 2 g intravenously every 8 h +/- Gentamicin ^{1,2,6} 3–5 mg/kg/d intravenously in 3 divided doses or Ciprofloxacin ¹ 400 mg intravenously every 8 h	Meropenem ¹ 2 g intravenously every 8 h +/- Gentamicin ^{1,2,6} 3–5 mg/kg/d intravenously in 3 divided doses or Ciprofloxacin ¹ 400 mg intravenously every 8 h	14–21 days
<i>Staphylococcus aureus</i> , <i>S epidermidis</i> (methicillin sensitive)	Nafcillin ⁵ 2 g intravenously every 4 h or Oxacillin ⁵ 2 g intravenously every 4 h	Vancomycin ^{1,2} 15 mg/kg intravenously every 8–12 h +/- Rifampin ³ 900–1200 mg/d intravenously or by mouth in 2–3 divided doses	14–21 days
<i>S aureus</i> , <i>S epidermidis</i> (methicillin-resistant)	Vancomycin ^{1,2} 15 mg/kg intravenously every 8–12 h +/- Rifampin ³ 900–1200 mg/d intravenously or by mouth in 2–3 divided doses	Linezolid 600 mg intravenously or by mouth every 12 h	14–21 days

¹ Dose adjust for renal insufficiency.² Monitoring of serum drug levels is recommended to optimize dosing.³ Caution in patients with hepatic insufficiency, dose adjustment may be required.⁴ Monitor for bone marrow suppression, including leukopenia, thrombocytopenia, and aplastic anemia.⁵ Dose adjustments may be indicated in patients who have combined hepatic and renal insufficiency.⁶ Once-daily dosing of gentamicin has been evaluated in an animal model suggesting superior central nervous system penetration versus conventional dosing.Data from Lewin JJ, LaPointe M, Ziai WC. Central nervous system infections in the critically ill. *Journal of Pharmacy Practice* 2005;18(1):25–41.

infection site). In nonimmunosuppressed individuals, initial coverage with vancomycin, ceftriaxone (or cefotaxime), and metronidazole is recommended [108]. Antibiotics should be tailored to the causative organism when microbiologic data become available. Given the frequent implication of anaerobic bacteria, however, metronidazole often is continued, even if an anaerobic source is not identified on culture. This is because of the fastidious nature of anaerobic bacteria resulting in a low yield when cultured.

Patients who have had recent neurosurgery or head trauma with a presumed nosocomial source of infection should be treated with a third- or fourth-generation cephalosporin with antipseudomonal activity (ceftazidime or cefepime) along with vancomycin (to cover MRSA or methicillin-resistant *S. epidermidis* (MRSE)) and metronidazole. In patients who have HIV, consideration should be given to empiric therapy to cover *Toxoplasma* with sulfadiazine and pyrimethamine (along with folinic acid). Addition of amphotericin B should be considered in neutropenic and post-transplant patients to cover fungal sources such as *Aspergillus*, *Cryptococcus*, and *Mucorales*. If *Nocardia* is suspected, trimethoprim/sulfamethoxazole should be added to the empiric regimen [108,112]. In most cases of brain abscess, treatment is continued for 6 to 8 weeks depending on the clinical and radiographic response.

Epidural abscess

Empiric treatment of cranial epidural abscess consists of broad-spectrum antibiotics, usually in combination with surgical drainage to prevent development of subdural empyema. The most common infectious etiologies include streptococci, staphylococci, and anaerobes, and infections are often polymicrobial [55,56]. Initial treatment with vancomycin, ceftriaxone (or cefotaxime), and metronidazole is appropriate in most cases. Substitution of ceftriaxone with ceftazidime or cefepime or meropenem is suggested where *Pseudomonas aeruginosa* or other resistant gram-negative nosocomial pathogens are suspected, such as after recent neurosurgery or trauma.

Spinal epidural abscess is usually a result of hematogenous spread, with bacteria directly seeding the epidural space. Alternatively, it may be a complication of adjacent discitis or vertebral osteomyelitis. Surgery of the spine, neuraxial anesthesia/analgesia, and LP also have been associated with spinal epidural abscess [55,56,113]. The most common organism involved is *S. aureus*, occurring in 60% to 90% of cases [113,114]. Other causative organisms include aerobic and anaerobic streptococcal species and gram-negative organisms such as *E. coli* and *P. aeruginosa* [55,56]. Emergent surgical decompression often is indicated to prevent ensuing neurological deficits. In addition, empiric antimicrobials, based on the most likely pathogens, should be initiated immediately. In most instances, vancomycin combined with a cephalosporin with antipseudomonal activity (ceftazidime or cefepime), or a carbapenem (meropenem), is indicated until culture results can provide information to optimize therapy. In selected cases, however, where the

patient does not have risk factors for nosocomial drug-resistant organisms (such as recent or prolonged hospitalization or recent surgery), empiric therapy with nafcillin (or oxacillin), combined with a third-generation cephalosporin (ceftriaxone or cefotaxime) may be appropriate. Antibiotic coverage should be narrowed once culture data are available, and treatment should continue for 3 to 4 weeks. In the setting of vertebral osteomyelitis or discitis, treatment for 4 to 6 weeks is indicated [55].

Subdural empyema

Successful management of subdural empyema usually requires early surgical evacuation in addition to appropriate antibiotic therapy. Empiric antibiotic selection for subdural empyema is the same as for intracranial epidural abscess, as the bacteriology of these infections is identical [58].

Viral encephalitis

In most instances, treatment of viral encephalitis is largely supportive and includes optimization of fluid balance and electrolytes; symptomatic treatment of fever, headache, and nausea; airway protection; management of ICP; and management of seizures. For HSE encephalitis, early treatment with acyclovir (10 mg/kg intravenously every 8 hours for 14 to 21 days) is associated with improved mortality and morbidity. When viral encephalitis is suspected, this therapy usually is started empirically until diagnostic confirmation is obtained (usually by CSF PCR) [115–117]. Dose adjustments are necessary in patients who have renal insufficiency. In addition, adequate hydration should be maintained during treatment, as acyclovir can cause a crystal nephropathy that is usually reversible.

CMV encephalitis is an opportunistic pathogen most commonly seen in transplant recipients and other immunosuppressed patients [118]. Optimal treatment of CMV encephalitis has not been well-studied. Current recommendations call for a combination of ganciclovir (5 mg/kg intravenously every 12 hours) and foscarnet (90 mg/kg intravenously every 12 hours, or 60 mg/kg intravenously every 8 hours) [118–120]. Ganciclovir and foscarnet are associated with severe adverse effects, including renal insufficiency, bone marrow suppression, encephalopathy, and seizures. Both require careful monitoring and dose adjustment in the setting of renal dysfunction [121].

Fungal central nervous system infection

Fungal infections of the CNS are encountered more commonly as opportunistic infections in the immunosuppressed population. Fungi may cause meningoencephalitis and brain abscess or granuloma. Causative organisms may include: *Cryptococcus neoformans*, *Coccidioides immitis*, *Histoplasma capsulatum*, *Candida albicans*, *Sporothrix schenckii*, *Blastomyces dermatidis*, *Zygomycetes* species, and *Aspergillus* species, with the latter two more commonly causing brain abscess [122].

Optimal treatment of CNS fungal infections is ill-defined. Although newer antifungal agents have emerged in recent years, the incidence of invasive fungal infections is rising, and outcomes in general are poor [123]. Most treatment regimens consist of an initial induction phase with an amphotericin-based regimen that lasts 2 to 6 weeks depending on clinical response. This is followed by a chronic suppressive phase with a triazole antifungal with activity against the pathogen being treated (usually fluconazole or voriconazole) that can last anywhere from 6 weeks to lifelong suppression. Optimal treatment also should include management of risk factors for fungal disease, such as hyperglycemia, and the minimization or elimination of immunosuppressants where appropriate.

Although amphotericin B is considered the first-line agent for most CNS fungal infections, it has a large molecular weight and has poor penetration of the BBB. For this reason flucytosine frequently is added to amphotericin B in the treatment of cryptococcal, *Candida*, and *Aspergillus* CNS infections. The dose of amphotericin B deoxycholate (AmB) is 1 mg/kg intravenously daily, combined with flucytosine 25 mg/kg orally every 6 hours. Higher doses (1.5 mg/kg daily), however, are recommended in the setting of mucormycosis [124]. Flucytosine requires dose adjustment in the setting of renal insufficiency, and serum levels should be monitored. Levels greater than 100 µg/mL are associated with an increased risk of bone marrow depression, which can be irreversible and result in death [125,126]. The goal peak flucytosine level is 70 to 80 µg/mL (drawn 4 hours after a dose at steady state), and the goal trough level is 30 to 40 µg/mL.

In patients who have renal insufficiency or who develop renal insufficiency, selection of a lipid-based amphotericin product is recommended. Both liposomal amphotericin B (L-amB) (5 mg/kg/d) and amphotericin B lipid complex (ABLC) (5 mg/kg/d) have been evaluated in a small number of patients, and they appear to have efficacy similar to conventional amphotericin B [127–129]. There are substantial differences between the amphotericin B products with respect to particle size, electrical charge, and volume of distribution, all of which have the potential to influence CNS penetration and antifungal activity. An animal model of *C albicans* CNS infection has demonstrated greater antifungal efficacy with AmB and L-AmB over ABLC and amphotericin B colloidal dispersion, but the clinical relevance of these findings has yet to be demonstrated [130].

Voriconazole represents a promising therapy for managing susceptible CNS fungal infections, in particular invasive aspergillosis. Voriconazole possesses a favorable pharmacokinetic profile with respect to CNS infections, as it penetrates the CSF with a median CSF:plasma ratio of 0.5 [131]. Schwartz and colleagues conducted a retrospective analysis of voriconazole in 81 patients who had CNS aspergillosis [132], among whom 35% had a complete or partial response. Thirty-one percent of patients survived for a median time of 390 days. It is worth noting that 31 of the 81 patients (38%) had neurosurgical intervention for the infection, which in

a multivariate analysis was associated with improved survival ($P = .02$), making it difficult to clearly discern the impact of voriconazole on outcomes. Considering that most published estimates of mortality associated with CNS aspergillosis approach 100% [133], however, this study suggests voriconazole is a reasonable option for CNS aspergillosis, and as an alternative for other susceptible CNS fungal infections when an amphotericin-based regimen cannot be tolerated. Initial dosing of voriconazole is 6 mg/kg intravenously every 12 hours for two doses, followed by 4 mg/kg intravenously every 12 hours. Voriconazole is metabolized by the hepatic CYP isoenzymes CYP2C9, CYP2C19, and CYP3A4 and is susceptible to numerous drug interactions, with many combinations being contraindicated. A thorough review of the patient's medication regimen for such interactions is indicated whenever starting a course of therapy.

Caspofungin is the first of a new class of antifungals (echinocandins) that target the fungal cell wall through inhibition of β -1,3 glucan synthesis. Caspofungin is highly protein-bound and has a large molecular weight and a small volume of distribution, all of which are linked to poor CNS penetration. In addition, animal data suggest that the brain tissue:plasma ratio is approximately 0.1 [134]. Hsue and colleagues reported a case of treatment failure associated with the use of caspofungin for meningeal coccidiomycosis [135]. In this report, CSF concentrations were undetectable despite adequate serum concentrations. Despite some sporadic reports of treatment successes [136,137], routine use of caspofungin in CNS fungal disease cannot be recommended at this time.

Given the poor CNS penetration of AmB and its significant systemic toxicities, there has been some interest in the use of intrathecal AmB for treating invasive CNS fungal infections. It can be administered through a reservoir device or as an intrathecal or intracisternal injection, and it typically is given in conjunction with systemic AmB and flucytosine. Dose ranges for intrathecal AmB range from 0.01 to 1.5 mg, and intervals range from daily to weekly [138,139]. Adverse effects associated with intrathecal AmB include arachnoiditis, paraplegia, paresthesias, nausea, vomiting, headache, and back pain. Hydrocortisone (15 to 25 mg) can be added to the intrathecal mixture in an effort to prevent toxicities. In addition, prophylactic administration of antipyretics and antiemetics may help alleviate some of the toxicities. Because of the invasiveness of intrathecal administration and associated toxicity, intrathecal AmB should be reserved for patients who have not responded to systemic therapy, or those who have relapsed.

Therapeutic controversies

Glucocorticoids for bacterial meningitis

Although it is accepted that inflammatory mechanisms contribute to the morbidity associated with bacterial meningitis, debate continues regarding

the appropriate use of anti-inflammatory drugs in particular glucocorticoids. The rationale for use of steroids is based on experimental data that show that the inflammatory response in the subarachnoid space contributes significantly to the morbidity and mortality of bacterial meningitis [27]. De Gans and colleagues [140] demonstrated in a large prospective randomized controlled trial that dexamethasone given before or with the first dose of antibiotic and then every 6 hours for 4 days improved the outcome in adults with acute bacterial meningitis, particularly pneumococcal meningitis without serious adverse effects. Unfavorable outcomes were reduced from 25% to 15% and mortality from 15% to 7% in dexamethasone-treated patients. On the basis of this study, the Infectious Diseases Society of America Practice Guideline recommends use of dexamethasone (0.15 mg/kg every 6 hours for 2 to 4 days) in patients who have suspected meningitis [75]. Dexamethasone should be continued only in patients with gram-positive diplococci on Gram's stain or *S pneumoniae* in CSF or blood cultures. It should not be given to patients with prior administration of antibiotics. Generalizability of the study results has been questioned, as initial antibiotic therapy consisted of amoxicillin or penicillin in most patients (77%), and less than 1% of isolates were resistant to penicillin. A systematic review including five clinical trials has since confirmed significant reductions in mortality and neurological sequelae in children with meningitis who receive dexamethasone therapy, with a trend toward benefit in adults [141].

A major concern is the rapidly rising incidence of highly resistant *S pneumoniae* requiring combination therapy with vancomycin. Vancomycin penetration into the CNS is largely dependent upon meningeal inflammation, and experimental studies show that dexamethasone significantly decreases the achievement of therapeutic vancomycin concentrations in the CSF [142,143], resulting in clinical treatment failure in adults [144]. Nevertheless, expert opinion recommends adjuvant dexamethasone even in patients with highly resistant pneumococcal isolates [145]. There are no data to support adjunctive steroids in patients who have nosocomial and postneurosurgical meningitis, and meningitis related to CSF shunts.

In patients who have TB meningitis, a randomized double-blind, placebo-controlled study of 545 patients conducted in Vietnam demonstrated that adjunctive treatment with dexamethasone reduces mortality (31.8% versus 41.3%), but probably does not prevent severe disability (18.2% versus 13.8%) [146]. The prespecified subgroup analysis of patients with HIV demonstrated a nonsignificant reduction in the risk of death, although none were treated with antiretroviral drugs, and the results may not be generalizable to populations with access to antiretroviral treatment. The results of this trial suggest that for non-HIV patients with TB meningitis, 4 to 8 weeks of dexamethasone (2 to 4 weeks of tapering intravenous steroids followed by tapering oral therapy) should be administered.

Intraventricular/intrathecal antibiotics

The question of intraventricular antimicrobial therapy arises most commonly in patients with CSF infections who have a CSF shunt or EVD. There is level III evidence for the instillation of antimicrobial agents into the ventricles in difficult-to-eradicate shunt infections or in patients who cannot undergo surgical management [75]. Although no antimicrobial agent is approved by the Food and Drug Administration for intraventricular use, common empirically used agents include vancomycin, gentamicin, and tobramycin. The usual dose of intraventricular vancomycin is 10 to 20 mg/d, continued for a few days after CSF cultures become negative. Potential adverse effects of intraventricular vancomycin include ototoxicity, CSF eosinophilia, seizures, altered mental status, and local tissue irritation [105,147]. In cases of fulminant gram-negative ventriculitis, intraventricular aminoglycosides have been used, although with less encouraging results [147–152]. Toxicities are similar to those of vancomycin. The usual daily dose of intraventricular gentamicin and tobramycin is 5 to 10 mg, and that of amikacin is 10 to 15 mg [148,151]. Redosing is determined by calculation of the inhibitory quotient (trough CSF concentration divided by the minimum inhibitory concentration of the agent for the isolated pathogen). This number should exceed 10 to 20 for consistent CSF sterilization [153]. It is important to use preservative-free formulations for intraventricular administration.

Prophylactic and perioperative antibiotics for neurosurgical procedures and external ventricular drains

Nosocomial meningitis accounted for 40% of acute adult bacterial meningitis in a review of 493 episodes, of which 81% occurred within 1 month of neurosurgery or head injury [32]. A recent retrospective study found an overall meningitis rate of 1.52% [67] in 6243 patients undergoing craniotomy, among whom 17% did not receive perioperative antibiotics. Independent risk factors for meningitis were CSF leakage, concomitant incision infection, male sex, and duration of surgery. Perioperative antibiotic prophylaxis reduced incidence of incision infections from 8.8% to 4.6% ($P < .0001$), but did not prevent meningitis. In patients receiving antibiotics, microorganisms were mainly noncutaneous and tended to be less susceptible to prophylactic antibiotics administered. These microorganisms also were associated with a higher mortality rate compared with meningitis caused by cutaneous organisms. The authors recommended narrow-spectrum antibiotics be used to prevent surgical site infections without any effect on the risk of meningitis.

A retrospective study of 308 patients compared prophylactic antibiotics administered for the duration of the EVDs with perioperative antibiotics, finding an overall rate of ventriculitis that was almost identical in the two groups [154]. The use of continuous prophylactic antibiotics was

discouraged based on the risk of selecting resistant organisms. To resolve this issue, a prospective randomized controlled study is needed.

The efficacy of antimicrobial-impregnated EVDs (with minocycline and rifampin) was evaluated in a prospective randomized controlled trial of 288 patients (mainly subarachnoid hemorrhage [SAH] and trauma) requiring EVDs [155]. The antibiotic-impregnated catheters were half as likely to become colonized as the control catheters (17.9% versus 36.7%; $P < 0.0012$) and seven times less likely to be associated with positive CSF cultures (1.3% versus 9.4%; $P = .002$). Heparin-coated catheters, which have been shown to lower the incidence of bacterial colonization and septicemia in central venous catheters [156] also have been evaluated in a randomized controlled study of 198 patients requiring EVDs (again mostly SAH and trauma) but demonstrated no benefit with regards to catheter colonization when compared with non heparin-coated EVDs. Finally, a hydrogel-coated EVD, which has a proposed advantage of reducing clot and bacterial adhesion, was evaluated in a prospective randomized trial. This also failed to demonstrate reduction in bacterial colonization [153].

Summary

The management of patients who have CNS infections is challenging. Therapy for CNS infections is evolving in light of changing microbial resistance patterns and with the introduction of new antimicrobial agents. Knowledge of cerebral inflammation, molecular diagnostics, and the evolving microbial epidemiology are important to optimizing therapy in patients with meningitis. Future investigations into the role of selective immunomodulation and other neuroprotective strategies may lead to significant advances in the management of CNS infection.

Acknowledgments

The authors would like to gratefully acknowledge the contribution of Brian Cole for his drawing of Fig. 1.

References

- [1] Wenger JD, Hightower AW, Facklam RR, et al. Bacterial meningitis in the United States, 1986: report of a multistate surveillance study. The Bacterial Meningitis Study Group. *J Infect Dis* 1990;162(6):1316–23.
- [2] Quagliarello V, Scheld WM. Bacterial meningitis: pathogenesis, pathophysiology, and progress. *N Engl J Med* 1992;327(12):864–72.
- [3] Plaut AG. The IgA1 proteases of pathogenic bacteria. *Annu Rev Microbiol* 1983;37:603–22.
- [4] Fearon DT. Regulation by membrane sialic acid of beta 1H-dependent decay-dissociation of amplification C3 convertase of the alternative complement pathway. *Proc Natl Acad Sci U S A* 1978;75(4):1971–5.

- [5] Rubin LL, Staddon JM. The cell biology of the blood–brain barrier. *Annu Rev Neurosci* 1999;22:11–28.
- [6] Wolburg H, Risau W, editors. Formation of the blood–brain barrier. Oxford (UK): Oxford University Press; 1995.
- [7] Quagliarello VJ, Wispelwey B, Long WJ Jr, et al. Recombinant human interleukin-1 induces meningitis and blood-brain barrier injury in the rat. Characterization and comparison with tumor necrosis factor. *J Clin Invest* 1991;87(4):1360–6.
- [8] Tuomanen E, Tomasz A, Hengstler B, et al. The relative role of bacterial cell wall and capsule in the induction of inflammation in pneumococcal meningitis. *J Infect Dis* 1985;151(3): 535–40.
- [9] Tofte RW, Peterson PK, Kim Y. Opsonic activity in normal human cerebrospinal fluid for selected bacterial species. *Infect Immun* 1979;26:1093–8.
- [10] Thea D, Barza M. Use of antibacterial agents in infections of the central nervous system. *Infect Dis Clin North Am* 1989;3:553–70.
- [11] Blamire AM, Anthony DC, Rajagopalan B, et al. Interleukin-1beta-induced changes in blood–brain barrier permeability, apparent diffusion coefficient, and cerebral blood volume in the rat brain: a magnetic resonance study. *J Neurosci* 2000;20(21): 8153–9.
- [12] Paul R, Koedel U, Winkler F, et al. Lack of IL-6 augments inflammatory response but decreases vascular permeability in bacterial meningitis. *Brain* 2003;126:1873–82.
- [13] Yang GY, Gong C, Qin Z, et al. Tumor necrosis factor alpha expression produces increased blood–brain barrier permeability following temporary focal cerebral ischemia in mice. *Brain Res Mol Brain Res* 1999;69(1):135–43.
- [14] Dietrich JB. The adhesion molecule ICAM-1 and its regulation in relation with the blood–brain barrier. *J Neuroimmunol* 2002;128(1–2):58–68.
- [15] Merrill JE, Murphy SP. Inflammatory events at the blood brain barrier: regulation of adhesion molecules, cytokines, and chemokines by reactive nitrogen and oxygen species. *Brain Behav Immun* 1997;11(4):245–63.
- [16] Petty MA, Lo EH. Junctional complexes of the blood–brain barrier: permeability changes in neuroinflammation. *Prog Neurobiol* 2002;68(5):311–23.
- [17] Stamatovic SM, Dimitrijevic OB, Keep RF, et al. Inflammation and brain edema: new insights into the role of chemokines and their receptors. *Acta Neurochir Suppl (Wien)* 2006; 96:444–50.
- [18] Hosomi N, Ban CR, Naya T, et al. Tumor necrosis factor-alpha neutralization reduced cerebral edema through inhibition of matrix metalloproteinase production after transient focal cerebral ischemia. *J Cereb Blood Flow Metab* 2005;25(8):959–67.
- [19] Oprica M, Van Dam AM, Lundkvist J, et al. Effects of chronic overexpression of interleukin-1 receptor antagonist in a model of permanent focal cerebral ischemia in mouse. *Acta Neuropathol (Berl)* 2004;108(1):69–80.
- [20] Aminpour S, Tinling SP, Brodie HA. Role of tumor necrosis factor-alpha in sensorineural hearing loss after bacterial meningitis. *Otol Neurotol* 2005;26(4):602–9.
- [21] Bifare YD, Kummer J, Joss P, et al. Brain-derived neurotrophic factor protects against multiple forms of brain injury in bacterial meningitis. *J Infect Dis* 2005;191(1):40–5.
- [22] Grant GA, Janigro D. The blood–brain barrier. In: Youmans JR, Becker DP, editors. *Youmans Neurological Surgery*, Volume 1. 5th edition. Philadelphia: Saunders; 2004. p. 153–9.
- [23] Lapointe M, Haines SJ, Landesman S. Basic principles of antimicrobial therapy of CNS infections. In: Cooper PR, Golfinos JG, editors. *Head injury*, Volume 1. 4th edition. New York: McGraw-Hill; 2000. p. 483–98.
- [24] Bleck T, Greenlee J. Central nervous system infections. In: Mandell G, Bennett J, Dolin R, editors. *Principles and practice of infectious diseases*, Volume 1. 5th edition. Philadelphia: Churchville Livingstone; 2000. p. 950–60.
- [25] Ristuccia AM, LeFrock JL. Cerebrospinal fluid penetration of antimicrobials. *Antimicrob Agents Chemother* 1992;45:118–52.

- [26] Brivet FG, Ducuing S, Jacobs F, et al. Accuracy of clinical presentation for differentiating bacterial from viral meningitis in adults: a multivariate approach. *Intensive Care Med* 2005; 31(12):1654–60.
- [27] Tunkel A, Scheld W. Acute meningitis. In: Mandell G, Bennett J, Dolin R, editors. *Principles and practice of infectious disease*, Volume 1. 5th edition. Philadelphia: Churchville Livingstone; 2000. p. 959–97.
- [28] Quagliarello VJ, Scheld WM. Treatment of bacterial meningitis. *N Engl J Med* 1997; 336(10):708–16.
- [29] van de Beek D, de Gans J, Spanjaard L, et al. Clinical features and prognostic factors in adults with bacterial meningitis. *N Engl J Med* 2004;351(18):1849–59.
- [30] Roos K, Tunkel A, Scheld W, et al. Acute bacterial meningitis in children and adults. In: Scheld W, Whitley R, Durack D, editors. *Infections of the central nervous system*. 2nd edition. Philadelphia: Lippincott-Raven; 1997. p. 335–402.
- [31] Diamond M. *Cryptococcal neoformans*. New York: Churchill-Livingstone; 2000.
- [32] Durand ML, Calderwood SB, Weber DJ, et al. Acute bacterial meningitis in adults. A review of 493 episodes. *N Engl J Med* 1993;328(1):21–8.
- [33] Pfister HW, Feiden W, Einhaupl KM. Spectrum of complications during bacterial meningitis in adults. Results of a prospective clinical study. *Arch Neurol* 1993;50(6): 575–81.
- [34] Hussein AS, Shafran SD. Acute bacterial meningitis in adults. A 12-year review. *Medicine (Baltimore)* 2000;79(6):360–8.
- [35] Igarashi M, Gilmartin RC, Gerald B, et al. Cerebral arteritis and bacterial meningitis. *Arch Neurol* 1984;41(5):531–5.
- [36] Sejvar JJ. The evolving epidemiology of viral encephalitis. *Curr Opin Neurol* 2006;19(4): 350–7.
- [37] Chretien F, Belec L, Hilton DA, et al. Herpes simplex virus type 1 encephalitis in acquired immunodeficiency syndrome. *Neuropathol Appl Neurobiol* 1996;22(5):394–404.
- [38] Hamilton RL, Achim C, Grafe MR, et al. Herpes simplex virus brainstem encephalitis in an AIDS patient. *Clin Neuropathol* 1995;14(1):45–50.
- [39] Bertram M, Schwarz S, Hacke W. Acute and critical care in neurology. *Eur Neurol* 1997; 38(3):155–66.
- [40] Johnson RT. Acute encephalitis. *Clin Infect Dis* 1996;23(2):219–24.
- [41] Schmutzhard E. Viral infections of the CNS with special emphasis on herpes simplex infections. *J Neurol* 2001;248(6):469–77.
- [42] Granwehr BP, Lillibridge KM, Higgs S, et al. West Nile virus: where are we now? *Lancet Infect Dis* 2004;4(9):547–56.
- [43] O'Leary DR, Marfin AA, Montgomery SP, et al. The epidemic of West Nile virus in the United States, 2002. *Vector Borne Zoonotic Dis* 2004;4(1):61–70.
- [44] Sejvar JJ, Haddad MB, Tierney BC, et al. Neurologic manifestations and outcome of West Nile virus infection. *JAMA* 2003;290(4):511–5.
- [45] Solomon T, Vaughn DW. Pathogenesis and clinical features of Japanese encephalitis and West Nile virus infections. *Curr Top Microbiol Immunol* 2002;267:171–94.
- [46] Pepperell C, Rau N, Krajden S, et al. West Nile virus infection in 2002: morbidity and mortality among patients admitted to hospital in southcentral Ontario. *CMAJ* 2003;168(11): 1399–405.
- [47] Sejvar JJ, Bode AV, Marfin AA, et al. West Nile virus-associated flaccid paralysis. *Emerg Infect Dis* 2005;11(7):1021–7.
- [48] Solomon T, Willison H. Infectious causes of acute flaccid paralysis. *Curr Opin Infect Dis* 2003;16(5):375–81.
- [49] Alpert SG, Fergerson J, Noel LP. Intrauterine West Nile virus: ocular and systemic findings. *Am J Ophthalmol* 2003;136(4):733–5.
- [50] Medarov BI, Multz AS, Brown W, et al. West Nile meningoencephalitis and rhabdomyolysis. *Lancet Infect Dis* 2005;5(1):2.

- [51] West Nile virus activity—United States, January 1–November 7, 2006. *MMWR Morb Mortal Wkly Rep* 2006;55(44):1204–5.
- [52] Civen R, Villacorte F, Robles DT, et al. West Nile virus infection in the pediatric population. *Pediatr Infect Dis J* 2006;25(1):75–8.
- [53] Sagher O, Leveque JC. Surgical management of CNS infections. In: Scheld W, Whitley R, Durack D, editors. *Infections of the central nervous system*. 2nd edition. Philadelphia: Lippincott-Raven; 1997. p. 945–72.
- [54] Wijdicks E. Acute bacterial infections of the central nervous system. In: Wijdicks E, editor. *Neurologic catastrophes in the emergency department*. Boston: Butterworth Heinemann; 2000. p. 183–94.
- [55] Armstrong W, Boulis N, McGillicuddy I. Infections of the central nervous system. In: Crockard H, Hoff J, editors. *Neurosurgery: the scientific basis of clinical practice*, Volume 2. 3rd edition. Oxford (UK): Blackwell Science; 2000. p. 757–83.
- [56] Bleck T, Greenlee J. Epidural abscess. In: Mandell G, Bennett J, Donlin R, editors. *Principles and practice of infectious diseases*, Volume 1. 5th edition. Philadelphia: Churchville Livingstone; 2000. p. 1031–4.
- [57] Zimmerman R, Girard N. Imaging of intracranial infections. In: Scheld W, Whitley R, Marra C, editors. *Infections of the central nervous system*. 3rd edition. Philadelphia: Lippincott-Raven; 2004. p. 31–56.
- [58] Bleck T, Greenlee J. Subdural Empyema. In: Mandell G, Bennett J, Donlin R, editors. *Principles and practice of infectious diseases*, Volume 1. 5th edition. Philadelphia: Churchville Livingstone; 2000. p. 1028–31.
- [59] Salmon JH. Ventriculitis complicating meningitis. *Am J Dis Child* 1972;124(1):35–40.
- [60] Miyairi I, Causey KT, DeVincenzo JP, et al. Group B streptococcal ventriculitis: a report of three cases and literature review. *Pediatr Neurol* 2006;34(5):395–9.
- [61] Smith A. Neonatal bacterial meningitis. In: Scheld W, Durack D, editors. *Infections of the central nervous system*. 2nd edition. Philadelphia: Lippincott-Raven; 1997. p. 328–9.
- [62] Lozier AP, Sciacca RR, Romagnoli MF, et al. Ventriculostomy-related infections: a critical review of the literature. *Neurosurgery* 2002;51(1):170–81.
- [63] Lyke KE, Obasanjo OO, Williams MA, et al. Ventriculitis complicating use of intraventricular catheters in adult neurosurgical patients. *Clin Infect Dis* 2001;33(12):2028–33.
- [64] Holloway KL, Barnes T, Choi S, et al. Ventriculostomy infections: the effect of monitoring duration and catheter exchange in 584 patients. *J Neurosurg* 1996;85(3):419–24.
- [65] Rebuck JA, Murry KR, Rhoney DH, et al. Infection related to intracranial pressure monitors in adults: analysis of risk factors and antibiotic prophylaxis. *J Neurol Neurosurg Psychiatry* 2000;69(3):381–4.
- [66] Sundbarg G, Nordstrom CH, Soderstrom S. Complications due to prolonged ventricular fluid pressure recording. *Br J Neurosurg* 1988;2(4):485–95.
- [67] Korinek AM, Reina M, Boch AL, et al. Prevention of external ventricular drain-related ventriculitis. *Acta Neurochir (Wien)* 2005;147(1):39–45 [discussion 45–36].
- [68] Swartz MN. Bacterial meningitis—a view of the past 90 years. *N Engl J Med* 2004;351(18):1826–8.
- [69] Hasbun R, Abrahams J, Jekel J, et al. Computed tomography of the head before lumbar puncture in adults with suspected meningitis. *N Engl J Med* 2001;345(24):1727–33.
- [70] Steigbigel NH. Computed tomography of the head before a lumbar puncture in suspected meningitis—is it helpful? *N Engl J Med* 2001;345(24):1768–70.
- [71] Mellor DH. The place of computed tomography and lumbar puncture in suspected bacterial meningitis. *Arch Dis Child* 1992;67(12):1417–9.
- [72] Aronin SI, Peduzzi P, Quagliarello VJ. Community-acquired bacterial meningitis: risk stratification for adverse clinical outcome and effect of antibiotic timing. *Ann Intern Med* 1998;129(11):862–9.
- [73] Coant PN, Kornberg AE, Duffy LC, et al. Blood culture results as determinants in the organism identification of bacterial meningitis. *Pediatr Emerg Care* 1992;8(4):200–5.

- [74] Coyle PK. Overview of acute and chronic meningitis. *Neurol Clin* 1999;17(4):691–710.
- [75] Tunkel AR, Hartman BJ, Kaplan SL, et al. Practice guidelines for the management of bacterial meningitis. *Clin Infect Dis* 2004;39(9):1267–84.
- [76] Leib SL, Boscacci R, Gratzl O, et al. Predictive value of cerebrospinal fluid (CSF) lactate level versus CSF/blood glucose ratio for the diagnosis of bacterial meningitis following neurosurgery. *Clin Infect Dis* 1999;29(1):69–74.
- [77] Deutch S, Pedersen LN, Podenphant L, et al. Broad-range real-time PCR and DNA sequencing for the diagnosis of bacterial meningitis. *Scand J Infect Dis* 2006;38(1):27–35.
- [78] Saravolatz LD, Manzor O, VanderVelde N, et al. Broad-range bacterial polymerase chain reaction for early detection of bacterial meningitis. *Clin Infect Dis* 2003;36(1):40–5.
- [79] Pai M, Flores LL, Pai N, Hubbard A, et al. Diagnostic accuracy of nucleic acid amplification tests for tuberculous meningitis: a systematic review and meta-analysis. *Lancet Infect Dis* 2003;3(10):633–43.
- [80] Thwaites GE, Caws M, Chau TT, et al. Comparison of conventional bacteriology with nucleic acid amplification (amplified mycobacterium direct test) for diagnosis of tuberculous meningitis before and after inception of antituberculosis chemotherapy. *J Clin Microbiol* 2004;42(3):996–1002.
- [81] Sormunen P, Kallio MJ, Kilpi T, et al. C-reactive protein is useful in distinguishing Gram stain-negative bacterial meningitis from viral meningitis in children. *J Pediatr* 1999;134(6):725–9.
- [82] Nathan BR, Scheld WM. The potential roles of C-reactive protein and procalcitonin concentrations in the serum and cerebrospinal fluid in the diagnosis of bacterial meningitis. *Curr Clin Top Infect Dis* 2002;22:155–65.
- [83] Gendrel D, Raymond J, Assicot M, et al. Measurement of procalcitonin levels in children with bacterial or viral meningitis. *Clin Infect Dis* 1997;24(6):1240–2.
- [84] Viallon A, Zeni F, Lambert C, et al. High sensitivity and specificity of serum procalcitonin levels in adults with bacterial meningitis. *Clin Infect Dis* 1999;28(6):1313–6.
- [85] Viallon A, Guyomarc'h P, Guyomarc'h S, et al. Decrease in serum procalcitonin levels over time during treatment of acute bacterial meningitis. *Crit Care* 2005;9(4):R344–50.
- [86] Martinez R, Gaul C, Buchfelder M, et al. Serum procalcitonin monitoring for differential diagnosis of ventriculitis in adult intensive care patients. *Intensive Care Med* 2002;28(2):208–10.
- [87] Dubos F, Moulin F, Gajdos V, et al. Serum procalcitonin and other biologic markers to distinguish between bacterial and aseptic meningitis. *J Pediatr* 2006;149(1):72–6.
- [88] Koskiniemi M, Piiparinen H, Mannonen L, et al. Herpes encephalitis is a disease of middle aged and elderly people: polymerase chain reaction for detection of herpes simplex virus in the CSF of 516 patients with encephalitis. The Study Group. *J Neurol Neurosurg Psychiatry* 1996;60(2):174–8.
- [89] Romero JR. Diagnosis and management of enteroviral infections of the central nervous system. *Curr Infect Dis Rep* 2002;4(4):309–16.
- [90] Kaplan SL, Mason EO Jr. Management of infections due to antibiotic-resistant *Streptococcus pneumoniae*. *Clin Microbiol Rev* 1998;11(4):628–44.
- [91] Kastrup O, Wanke I, Maschke M. Neuroimaging of infections. *NeuroRx* 2005;2(2):324–32.
- [92] Kumar R, Kohli N, Thavnani H, et al. Value of CT scan in the diagnosis of meningitis. *Indian Pediatr* 1996;33(6):465–8.
- [93] Andronikou S, Smith B, Hatherhill M, et al. Definitive neuroradiological diagnostic features of tuberculous meningitis in children. *Pediatr Radiol* 2004;34(11):876–85.
- [94] Kearney BP, Aweeka FT. The penetration of anti-infectives into the central nervous system. *Neurol Clin* 1999;17(4):883–900.
- [95] Houck PM, Bratzler DW, Nsa W, et al. Timing of antibiotic administration and outcomes for Medicare patients hospitalized with community-acquired pneumonia. *Arch Intern Med* 2004;164(6):637–44.

- [96] Iregui M, Ward S, Sherman G, et al. Clinical importance of delays in the initiation of appropriate antibiotic treatment for ventilator-associated pneumonia. *Chest* 2002;122(1):262–8.
- [97] Leibovici L, Shraga I, Drucker M, et al. The benefit of appropriate empirical antibiotic treatment in patients with bloodstream infection. *J Intern Med* 1998;244(5):379–86.
- [98] Ibrahim EH, Sherman G, Ward S, et al. The influence of inadequate antimicrobial treatment of bloodstream infections on patient outcomes in the ICU setting. *Chest* 2000;118(1):146–55.
- [99] Lu CH, Huang CR, Chang WN, et al. Community-acquired bacterial meningitis in adults: the epidemiology, timing of appropriate antimicrobial therapy, and prognostic factors. *Clin Neurol Neurosurg* 2002;104(4):352–8.
- [100] Schlech WF III, Ward JI, Band JD, et al. Bacterial meningitis in the United States, 1978 through 1981. The National Bacterial Meningitis Surveillance Study. *JAMA* 1985;253(12):1749–54.
- [101] Schuchat A, Robinson K, Wenger JD, et al. Bacterial meningitis in the United States in 1995. Active Surveillance Team. *N Engl J Med* 1997;337(14):970–6.
- [102] Pizon AF, Bonner MR, Wang HE, et al. Ten years of clinical experience with adult meningitis at an urban academic medical center. *J Emerg Med* 2006;30(4):367–70.
- [103] Blumberg HM, Burman WJ, Chaisson RE, et al. American Thoracic Society/Centers for Disease Control and Prevention/Infectious Diseases Society of America. Treatment of tuberculosis. *Am J Respir Crit Care Med* 2003;167(4):603–62.
- [104] Pfausler B, Spiss H, Beer R, et al. Treatment of staphylococcal ventriculitis associated with external cerebrospinal fluid drains: a prospective randomized trial of intravenous compared with intraventricular vancomycin therapy. *J Neurosurg* 2003;98(5):1040–4.
- [105] Luer MS, Hattton J. Vancomycin administration into the cerebrospinal fluid: a review. *Ann Pharmacother* 1993;27(7–8):912–21.
- [106] Bayston R, Hart CA, Barnicoat M. Intraventricular vancomycin in the treatment of ventriculitis associated with cerebrospinal fluid shunting and drainage. *J Neurol Neurosurg Psychiatry* 1987;50(11):1419–23.
- [107] Tenney JH. Bacterial infections of the central nervous system in neurosurgery. *Neurol Clin* 1986;4(1):91–114.
- [108] Calfee DP, Wispelwey B. Brain abscess. *Semin Neurol* 2000;20(3):353–60.
- [109] Seydoux C, Francioli P. Bacterial brain abscesses: factors influencing mortality and sequelae. *Clin Infect Dis* 1992;15(3):394–401.
- [110] Sofianou D, Selviarides P, Sofianos E, et al. Etiological agents and predisposing factors of intracranial abscesses in a Greek university hospital. *Infection* 1996;24(2):144–6.
- [111] Lu CH, Chang WN, Lui CC. Strategies for the management of bacterial brain abscess. *J Clin Neurosci* 2006;13(10):979–85.
- [112] Pruitt AA. Infections of the nervous system. *Neurol Clin* 1998;16(2):419–47.
- [113] Rigamonti D, Liem L, Sampath P, et al. Spinal epidural abscess: contemporary trends in etiology, evaluation, and management. *Surg Neurol* 1999;52(2):189–96 [discussion 197].
- [114] Nussbaum ES, Rigamonti D, Standiford H, et al. Spinal epidural abscess: a report of 40 cases and review. *Surg Neurol* 1992;38(3):225–31.
- [115] McGrath N, Anderson NE, Croxson MC, et al. Herpes simplex encephalitis treated with acyclovir: diagnosis and long-term outcome. *J Neurol Neurosurg Psychiatry* 1997;63(3):321–6.
- [116] Whitley RJ, Gnann JW. Viral encephalitis: familiar infections and emerging pathogens. *Lancet* 2002;359(9305):507–13.
- [117] Whitley RJ, Alford CA, Hirsch MS, et al. Vidarabine versus acyclovir therapy in herpes simplex encephalitis. *N Engl J Med* 1986;314(3):144–9.
- [118] Roos KL. Encephalitis. *Neurol Clin* 1999;17(4):813–33.
- [119] Chaudhuri A, Kennedy PG. Diagnosis and treatment of viral encephalitis. *Postgrad Med J* 2002;78(924):575–83.

- [120] Anduze-Faris BM, Fillet AM, Gozlan J, et al. Induction and maintenance therapy of cytomegalovirus central nervous system infection in HIV-infected patients. *AIDS* 2000;14(5): 517–24.
- [121] Balfour HH Jr. Antiviral drugs. *N Engl J Med* 1999;340(16):1255–68.
- [122] Davis LE. Fungal infections of the central nervous system. *Neurol Clin* 1999;17(4):761–81.
- [123] Go JL, Kim PE, Ahmadi J, et al. Fungal infections of the central nervous system. *Neuroimaging Clin N Am* 2000;10(2):409–25.
- [124] Mattiuzzi G, Giles FJ. Management of intracranial fungal infections in patients with haematological malignancies. *Br J Haematol* 2005;131(3):287–300.
- [125] Stamm AM, Diasio RB, Dismukes WE, et al. Toxicity of amphotericin B plus flucytosine in 194 patients with cryptococcal meningitis. *Am J Med* 1987;83(2):236–42.
- [126] Vermes A, Guchelaar HJ, Dankert J. Flucytosine: a review of its pharmacology, clinical indications, pharmacokinetics, toxicity, and drug interactions. *J Antimicrob Chemother* 2000;46(2):171–9.
- [127] Walsh TJ, Hiemenz JW, Seibel NL, et al. Amphotericin B lipid complex for invasive fungal infections: analysis of safety and efficacy in 556 cases. *Clin Infect Dis* 1998;26(6):1383–96.
- [128] Wong-Beringer A, Jacobs RA, Guglielmo BJ. Lipid formulations of amphotericin B: clinical efficacy and toxicities. *Clin Infect Dis* 1998;27(3):603–18.
- [129] Leenders AC, Reiss P, Portegies P, et al. Liposomal amphotericin B (AmBisome) compared with amphotericin B both followed by oral fluconazole in the treatment of AIDS-associated cryptococcal meningitis. *AIDS* 1997;11(12):1463–71.
- [130] Groll AH, Giri N, Petraitis V, et al. Comparative efficacy and distribution of lipid formulations of amphotericin B in experimental *Candida albicans* infection of the central nervous system. *J Infect Dis* 2000;182(1):274–82.
- [131] Pearson MM, Rogers PD, Cleary JD, et al. Voriconazole: a new triazole antifungal agent. *Ann Pharmacother* 2003;37(3):420–32.
- [132] Schwartz S, Ruhnke M, Ribaud P, et al. Improved outcome in central nervous system aspergillosis, using voriconazole treatment. *Blood* 2005;106(8):2641–5.
- [133] Lin SJ, Schranz J, Teutsch SM. Aspergillosis case fatality rate: systematic review of the literature. *Clin Infect Dis* 2001;32(3):358–66.
- [134] Hajdu R, Thompson R, Sundelof JG, et al. Preliminary animal pharmacokinetics of the parenteral antifungal agent MK-0991 (L-743,872). *Antimicrob Agents Chemother* 1997; 41(11):2339–44.
- [135] Hsue G, Napier JT, Prince RA, et al. Treatment of meningeal coccidioidomycosis with caspofungin. *J Antimicrob Chemother* 2004;54(1):292–4.
- [136] Liu KH, Wu CJ, Chou CH, et al. Refractory candidal meningitis in an immunocompromised patient cured by caspofungin. *J Clin Microbiol* 2004;42(12):5950–3.
- [137] Odio CM, Araya R, Pinto LE, et al. Caspofungin therapy of neonates with invasive candidiasis. *Pediatr Infect Dis J* 2004;23(12):1093–7.
- [138] Patel R. Antifungal agents. Part I. Amphotericin B preparations and flucytosine. *Mayo Clin Proc* 1998;73(12):1205–25.
- [139] Arthur RR, Drew RH, Perfect JR. Novel modes of antifungal drug administration. *Expert Opin Investig Drugs* 2004;13(8):903–32.
- [140] de Gans J, van de Beek D. Dexamethasone in adults with bacterial meningitis. *N Engl J Med* 2002;347(20):1549–56.
- [141] van de Beek D, de Gans J, McIntyre P, et al. Corticosteroids in acute bacterial meningitis. *Cochrane Database Syst Rev* 2003;(3):CD004405.
- [142] Lutsar I, Friedland IR, Jafri HS, et al. Factors influencing the anti-inflammatory effect of dexamethasone therapy in experimental pneumococcal meningitis. *J Antimicrob Chemother* 2003;52(4):651–5.
- [143] Cabellos C, Martinez-Lacasa J, Tubau F, et al. Evaluation of combined ceftriaxone and dexamethasone therapy in experimental cephalosporin-resistant pneumococcal meningitis. *J Antimicrob Chemother* 2000;45(3):315–20.

- [144] Viladrich PF, Gudiol F, Linares J, et al. Evaluation of vancomycin for therapy of adult pneumococcal meningitis. *Antimicrob Agents Chemother* 1991;35(12):2467–72.
- [145] van de Beek D, de Gans J. Dexamethasone in adults with community-acquired bacterial meningitis. *Drugs* 2006;66(4):415–27.
- [146] Thwaites GE, Nguyen DB, Nguyen HD, et al. Dexamethasone for the treatment of tuberculous meningitis in adolescents and adults. *N Engl J Med* 2004;351(17):1741–51.
- [147] Wen DY, Bottini AG, Hall WA, et al. Infections in neurologic surgery. The intraventricular use of antibiotics. *Neurosurg Clin N Am* 1992;3(2):343–54.
- [148] Wright PF, Kaiser AB, Bowman CM, et al. The pharmacokinetics and efficacy of an aminoglycoside administered into the cerebral ventricles in neonates: implications for further evaluation of this route of therapy in meningitis. *J Infect Dis* 1981;143(2):141–7.
- [149] McCracken GH Jr, Mize SG, Threlkeld N. Intraventricular gentamicin therapy in gram-negative bacillary meningitis of infancy. Report of the Second Neonatal Meningitis Cooperative Study Group. *Lancet* 1980;1(8172):787–91.
- [150] Wald SL, McLaurin RL. Cerebrospinal fluid antibiotic levels during treatment of shunt infections. *J Neurosurg* 1980;52(1):41–6.
- [151] Preston SL, Briceland LL. Intrathecal administration of amikacin for treatment of meningitis secondary to cephalosporin-resistant *Escherichia coli*. *Ann Pharmacother* 1993;27:870–3.
- [152] Haase KK, Lapointe M, Haines SJ. Aseptic meningitis after intraventricular administration of gentamicin. *Pharmacotherapy* 2001;21(1):103–7.
- [153] Kaufman B. Infections of cerebrospinal fluid shunts. In: Scheld W, Whitley R, Durack D, editors. *Infections of the central nervous system*. 2nd edition. Philadelphia: Lippincott-Raven; 1997. p. 555–77.
- [154] Alleyne CH Jr, Hassan M, Zabramski JM. The efficacy and cost of prophylactic and peri-procedural antibiotics in patients with external ventricular drains. *Neurosurgery* 2000;47(5):1124–7 [discussion 1127–9].
- [155] Zabramski JM, Whiting D, Darouiche RO, et al. Efficacy of antimicrobial-impregnated external ventricular drain catheters: a prospective, randomized, controlled trial. *J Neurosurg* 2003;98(4):725–30.
- [156] Appelgren P, Ransjo U, Bindslev L, et al. Surface heparinization of central venous catheters reduces microbial colonization in vitro and in vivo: results from a prospective, randomized trial. *Crit Care Med* 1996;24(9):1482–9.