

Management strategies for patients with pulmonary hypertension in the intensive care unit*

Roham T. Zamanian, MD; Francois Haddad, MD; Ramona L. Doyle, MD; Ann B. Weinacker, MD

LEARNING OBJECTIVES

On completion of this article, the reader should be able to:

1. Explain the pathophysiology of pulmonary hypertension.
2. Describe treatment modalities for pulmonary hypertension.
3. Use this information in the clinical setting.

Dr. Zamanian has disclosed that he is/was the recipient of grant/research funds from Entelligence-Actelion's Young Investigators Program, is/was on the speakers' bureau for Actelion, and was on the speakers' bureau for Co-Therix, and Encysive. Dr. Doyle has disclosed that she is/was a consultant for Actelion, Encysive, and Gilead. Dr. Haddad has disclosed that he has no financial relationships with or interests in any commercial companies pertaining to this educational activity. Dr. Weinacker has disclosed that she was the recipient of grant/research funds from Lilly.

The authors have disclosed that sildenafil has not been approved by the U.S. Food and Drug Administration for use in the treatment of pulmonary hypertension in critically ill patients. Please consult product labeling for the approved usage of this drug or device.

Lippincott CME Institute, Inc., has identified and resolved all faculty conflicts of interest regarding this educational activity.

Visit the *Critical Care Medicine* Web site (www.ccmjournal.org) for information on obtaining continuing medical education credit.

Objective: Pulmonary hypertension may be encountered in the intensive care unit in patients with critical illnesses such as acute respiratory distress syndrome, left ventricular dysfunction, and pulmonary embolism, as well as after cardiothoracic surgery. Pulmonary hypertension also may be encountered in patients with preexisting pulmonary vascular, lung, liver, or cardiac diseases. The intensive care unit management of patients can prove extremely challenging, particularly when they become hemodynamically unstable. The objective of this review is to discuss the pathogenesis and physiology of pulmonary hypertension and the utility of various diagnostic tools, and to provide recommendations regarding the use of vasopressors and pulmonary vasodilators in intensive care.

Data Sources and Extraction: We undertook a comprehensive review of the literature regarding the management of pulmonary hypertension in the setting of critical illness. We performed a MEDLINE search of articles published from January 1970 to March 2007. Medical subject headings and keywords searched and cross-referenced with each other were: pulmonary hypertension, vasopressor agents, therapeutics, critical illness, intensive care, right ventricular failure, mitral stenosis, prostacyclin, nitric oxide, sildenafil,

dopamine, dobutamine, phenylephrine, isoproterenol, and vasopressin. Both human and animal studies related to pulmonary hypertension were reviewed.

Conclusions: Pulmonary hypertension presents a particular challenge in critically ill patients, because typical therapies such as volume resuscitation and mechanical ventilation may worsen hemodynamics in patients with pulmonary hypertension and right ventricular failure. Patients with decompensated pulmonary hypertension, including those with pulmonary hypertension associated with cardiothoracic surgery, require therapy for right ventricular failure. Very few human studies have addressed the use of vasopressors and pulmonary vasodilators in these patients, but the use of dobutamine, milrinone, inhaled nitric oxide, and intravenous prostacyclin have the greatest support in the literature. Treatment of pulmonary hypertension resulting from critical illness or chronic lung diseases should address the primary cause of hemodynamic deterioration, and pulmonary vasodilators usually are not necessary. (*Crit Care Med* 2007; 35:2037–2050)

KEY WORDS: pulmonary hypertension; intensive care unit; vasopressor agents; nitric oxide; prostacyclin; right ventricular failure; dobutamine

Pulmonary hypertension is commonly encountered in the intensive care unit (ICU). Although new therapies for pulmonary hypertension have emerged in recent years, the management of criti-

cally ill patients with hemodynamically significant pulmonary hypertension remains challenging. Patients with moderate to severe pulmonary hypertension can deteriorate rapidly and are unlikely to survive efforts at cardiopulmonary resus-

citation (1). Appropriate therapy depends on identifying the underlying cause and hemodynamic effects of pulmonary hypertension. To reflect differences in pathophysiology, a revised World Health Organization classification of pulmonary

***See also p. 2210.**

Assistant Professor of Medicine (RTZ), Clinical Instructor (FH), Pulmonary Hypertension Clinical Service, Associate Professor, Co-Director, Vera Moulton Wall Center for Pulmonary Vascular Disease (RLD), Associate Professor of Medicine (ABW), Division of Pulmonary

& Critical Care Medicine, Associate Chair for Clinical Affairs, Department of Medicine (ABW), Stanford University Medical Center, Stanford, CA.

Supported, in part, by grants from Actelion (RZ, RLD) and United Therapeutics (RLD).

Address requests for reprints to: Ann B. Weinacker,

MD, 300 Pasteur Drive, S102, Stanford, CA 94305-5110. E-mail: annw@stanford.edu

Copyright © 2007 by the Society of Critical Care Medicine and Lippincott Williams & Wilkins

DOI: 10.1097/01.CCM.0000280433.74246.9E

hypertension (Table 1) has been adopted (2). The revised classification separates causes of pulmonary hypertension into those that primarily affect the pulmonary arterial tree (pulmonary arterial hypertension; PAH) or the pulmonary venous system, and those that affect the pulmonary vasculature because of alterations in lung structure or function. This new classification thus provides a framework to guide appropriate diagnosis and treatment of pulmonary hypertension in critically ill patients (2).

Pulmonary hypertension is defined as a systolic pulmonary artery pressure (PAP) of >35 mm Hg, or, alternatively, as a mean PAP of >25 mm Hg at rest or >30 mm Hg with exertion (2–4). Pulmonary hypertension in the ICU may be due to preexisting pulmonary vascular disease, lung disease, liver disease, or cardiac disease. Pulmonary hypertension also may be caused by critical illnesses such as acute respiratory distress syndrome (ARDS), acute left ventricular dysfunction, and pulmonary embolism, or may occur after cardiac or thoracic surgery. In this paper we review the diagnosis and treatment of critically ill patients with pulmonary hypertension of varying etiologies, and discuss strategies to treat hemodynamic instability.

PATHOGENESIS AND PHYSIOLOGY

Pulmonary hypertension encompasses a spectrum of pathologies best characterized by their anatomical location: precapillary arteries and arterioles, alveoli and capillary beds, and postcapillary pulmonary veins and venules. Idiopathic pulmonary arterial hypertension is the result of increased vasoconstriction, pulmonary vascular remodeling, and *in situ* thrombosis provoked by endothelial dysfunction, smooth muscle proliferation, and neointimal formation (3, 5, 6) in the precapillary arteries and arterioles. The more common causes of PAH (group 1 in Table 1) have similar histopathologic changes. Hypoxemic lung diseases such as interstitial lung disease and chronic obstructive pulmonary disease may cause pulmonary hypertension as the result of vascular destruction as well as alveolar hypoxemia. In acute lung injury, both hypoxemia and the accumulation of intravascular fibrin and cellular debris contribute to subsequent vascular obliteration and pulmonary hypertension (7).

Table 1. Revised clinical classification of pulmonary hypertension (Venice 2003)

-
1. Pulmonary arterial hypertension (PAH)
 - 1.1. Idiopathic (iPAH)
 - 1.2. Familial (FPAH)
 - 1.3. Associated with (APAH)
 - 1.3.1. Collagen vascular disease
 - 1.3.2. Congenital systemic-to-pulmonary shunts
 - 1.3.3. Portal hypertension
 - 1.3.4. HIV infection
 - 1.3.5. Drugs and toxins
 - 1.3.6. Other (thyroid disorders, glycogen storage disease, Gaucher disease, hereditary hemorrhagic telangiectasia, hemoglobinopathies, myeloproliferative disorders, splenectomy)
 - 1.4. Associated with significant venous or capillary involvement
 - 1.4.1. Pulmonary veno-occlusive disease (PVOD)
 - 1.4.2. Pulmonary capillary hemangiomatosis (PCH)
 - 1.5. Persistent pulmonary hypertension of the newborn
 2. Pulmonary hypertension with left heart disease
 - 2.1. Left-sided atrial or ventricular heart disease
 - 2.2. Left-sided valvular heart disease
 3. Pulmonary hypertension associated with lung diseases and/or hypoxemia
 - 3.1. Chronic obstructive pulmonary disease
 - 3.2. Interstitial lung disease
 - 3.3. Sleep-disordered breathing
 - 3.4. Alveolar hypoventilation disorders
 - 3.5. Chronic exposure to high altitude
 - 3.6. Developmental abnormalities
 4. Pulmonary hypertension due to chronic thrombotic and/or embolic disease
 - 4.1. Thromboembolic obstruction of proximal pulmonary arteries
 - 4.2. Thromboembolic obstruction of distal pulmonary arteries
 - 4.3. Non-thrombotic pulmonary embolism (tumor, parasites, foreign material)
 5. Miscellaneous

Sarcoidosis, histiocytosis X, lymphangiomatosis, compression of pulmonary vessels (adenopathy, tumor, fibrosing mediastinitis)
-

HIV, human immunodeficiency virus.

Reproduced with permission from Simmoneau G, Galie N, Rubin LJ, et al: Clinical classification of pulmonary hypertension. *J Am Coll Cardiol* 2004; 43:10S.

Pulmonary venous hypertension is typically a result of left ventricular diastolic dysfunction, valvular heart disease, or pulmonary venous disorders.

Multiple molecular pathways have been implicated in the pathogenesis of PAH. Nitric oxide and prostacyclin are endogenous vasodilators produced in the pulmonary vascular endothelium, and in many types of pulmonary hypertension their production is impaired (7, 8). Endothelin-1 is an endogenous vasoconstrictor peptide secreted by the vascular endothelium (7), and is implicated in pulmonary vasoconstriction and vascular smooth muscle proliferation (7). Endothelin-1 is excessively abundant in patients with idiopathic PAH, PAH associated with congenital heart disease, and pulmonary hypertension associated with thromboembolic disease (8–10). Dysfunction in the nitric oxide, prostacyclin, endothelin-1, and other pathways produces an imbalance between vasodilation and vasoconstriction, and between apoptosis and proliferation. The rationale for therapy

for PAH is thus based on re-establishing the balance in key molecular pathways by increasing available nitric oxide and prostacyclin, or reducing the effects of endothelin-1 (Fig. 1).

The neurotransmitter serotonin and the serotonin receptor transporter also have been implicated in the development of PAH. Some studies have linked high serotonin levels to PAH (11, 12). Furthermore, appetite suppressants such as dexfenfluramine and aminorex that elevate serotonin levels are associated with a significantly increased incidence of PAH (13). Recent debate has focused on the potential role of serotonin receptor transporter polymorphism as a genetic risk factor for developing PAH (14).

The consequence of these aberrant cellular and molecular pathways is an increase in pulmonary vascular resistance (PVR) and impedance of flow, causing right ventricular strain that impairs filling and causes right ventricular volume and pressure overload (Fig. 2). The right ventricle then dilates and eventually hypertrophy develops, encroaching on the

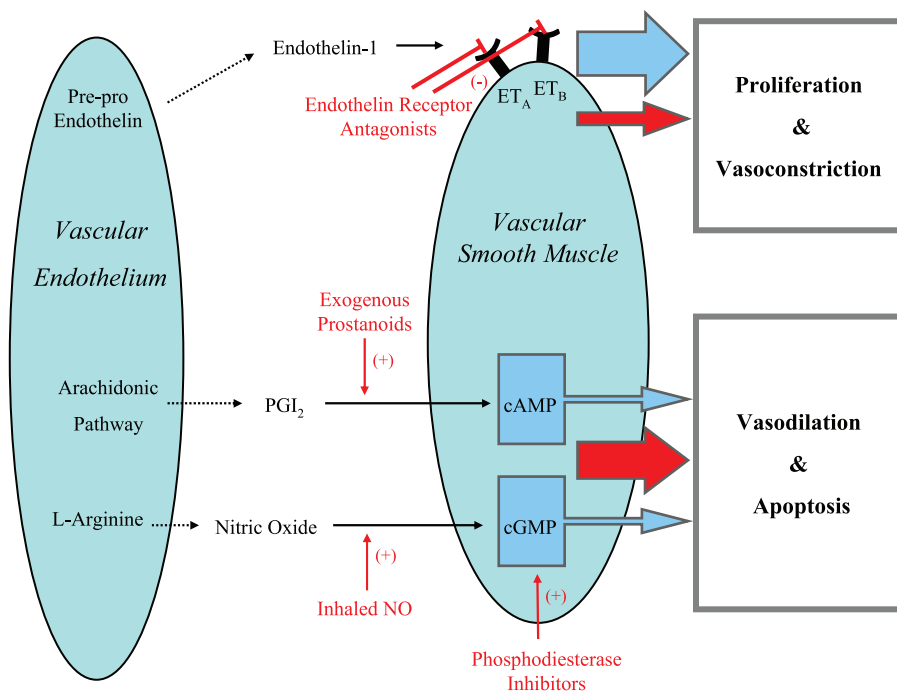


Figure 1. Schematic representation of pathways implicated in pulmonary arterial hypertension, and sites of action of current therapies. The overabundance of endothelin-1 and the relative lack of prostaglandin I_2 and nitric oxide lead to the vasoconstriction and hyperproliferation associated with pulmonary arterial hypertension (blue arrows). Therapies (red text) aimed at specific molecular pathways attempt to regain control of proliferation and hypertrophy of vascular smooth muscle and result in vasodilation (red arrows). ET_A , endothelin A; ET_B , endothelin B; $cAMP$, cyclic adenosine monophosphate; $cGMP$, cyclic guanosine monophosphate; NO , nitric oxide; PGI_2 , prostaglandin I_2 .

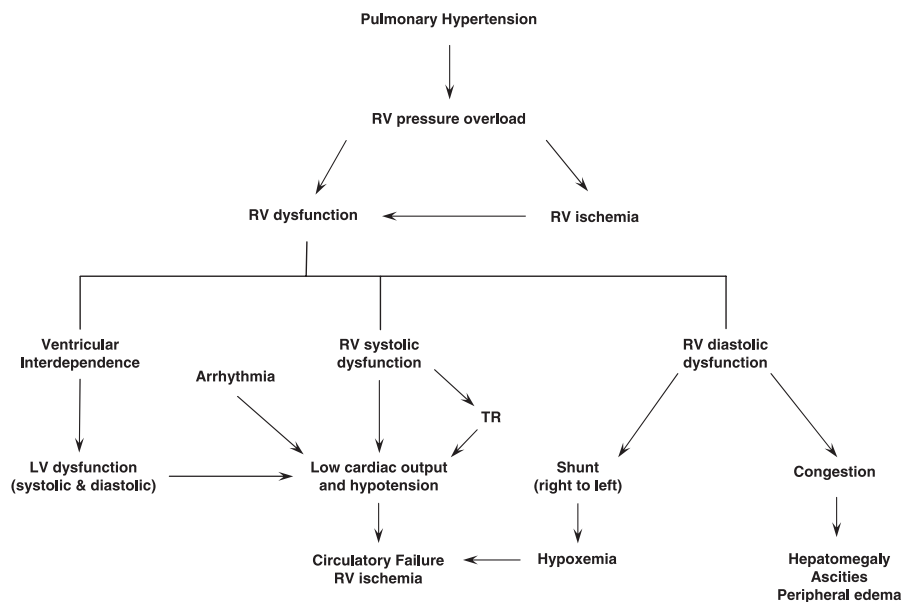


Figure 2. Implications of pulmonary hypertension on right ventricular (RV) function and hemodynamics. Development and progression of pulmonary hypertension leads to right ventricular pressure overload, which impacts right ventricular systolic and diastolic function. Left ventricular (LV) dysfunction also can result in the setting of right ventricular failure. The physiologic consequence of ventricular dysfunction in conjunction with development of arrhythmias, tricuspid regurgitation (TR), and worsening hypoxemia ultimately lead to hypotension and circulatory collapse.

left ventricle and decreasing preload, cardiac output, and coronary perfusion. Increased right ventricular wall stress results in right ventricular ischemia.

Tricuspid regurgitation develops as a result of right ventricular dysfunction and portends a poor prognosis (15). Regardless of the underlying cause of pulmonary

hypertension, the final common pathway for hemodynamic deterioration and death is right ventricular failure, which is the most challenging aspect of patient management. Therapy is thus aimed at acutely relieving right ventricular overload by decreasing PVR and reversing right ventricular failure with pulmonary vasodilators and inotropes.

RIGHT VENTRICULAR DYSFUNCTION IN PULMONARY HYPERTENSION

Compared with the left ventricle, the right ventricle demonstrates a heightened sensitivity to changes in afterload. Right ventricular stroke volume decreases proportionately to acute increases in afterload. In addition, a normal right ventricle cannot acutely increase the mean PAP to more than 40 mm Hg (16). Right ventricular systolic dysfunction, severe tricuspid regurgitation, arrhythmias, and left ventricular dysfunction caused by ventricular interdependence may contribute to low cardiac output and hypotension in patients with pulmonary hypertension (Fig. 2). Ventricular interdependence refers to the concept that the size, shape, and compliance of one ventricle may affect the size, shape, and pressure-volume relationship of the other ventricle. In the presence of right ventricular volume or pressure overload, the interventricular septum shifts toward the left and limits left ventricular filling and output. This has direct implications for the management of patients with pulmonary hypertension and acute right ventricular failure. In fact, the challenge is to find the optimal preload to avoid the detrimental effects of ventricular interdependence (17). Another consequence of right ventricular failure in the setting of pulmonary hypertension is the opening of the foramen ovale and development of right to left shunting that can cause or aggravate hypoxemia.

Neurohormonal activation is important in acute and chronic right-sided failure. Atrial and B-type natriuretic peptide levels recently have been described to be elevated in patients with right ventricular failure and pulmonary hypertension (18), and are not only markers for pulmonary hypertension but appear to be important in the pathogenesis of the disease. Atrial and B-type natriuretic peptides are cardiac peptides that not only promote diuresis but also inhibit pulmonary vasoconstriction

(including hypoxic pulmonary vasoconstriction) by raising cyclic guanosine monophosphate levels, and patients with pulmonary hypertension have been demonstrated to have decreased responsiveness to these peptides (18, 19).

DIAGNOSTIC TOOLS IN THE ICU

Pulmonary hypertension may first be recognized when an echocardiogram is obtained or a pulmonary artery catheter is placed for hemodynamic monitoring. Determining the cause and significance of the elevated PAP then dictates appropriate therapy. A comprehensive work-up is then necessary to determine the cause and hemodynamic consequence of pulmonary hypertension. Physical, laboratory, and radiologic examinations can help distinguish among three main causes of pulmonary hypertension in the ICU (preexisting pulmonary vascular disease, acute or chronic cardiovascular disease, and acute or chronic pulmonary disease), or other causes such as human immunodeficiency virus or liver disease.

Physical examination of patients with right ventricular failure classically reveals an elevated jugular venous pulse with a large *v* wave. An early finding is a prominent pulmonic component of the second heart sound. Other findings may include a palpable right ventricular heave, and the holosystolic blowing murmur of tricuspid regurgitation murmur along the left lower sternal border (20). If perceptible, accentuation of this murmur during inspiration (Carvallo's sign) distinguishes it from the murmurs of mitral regurgitation and aortic stenosis. There may be tender, even pulsatile hepatomegaly, and ascites or peripheral edema. The lung exam may suggest underlying lung disease. Patients with isolated right ventricular failure, however, do not exhibit pulmonary edema. The finding of pulmonary edema suggests left ventricular dysfunction, pulmonary venous hypertension, or a noncardiac cause such as ARDS.

Laboratory evaluation is undertaken to identify reversible causes of pulmonary hypertension. In the ICU however, many laboratory derangements result from critical illness itself. Nonetheless, clues may be provided as to the underlying cause of pulmonary hypertension by polycythemia (suggesting chronic hypoxemia), thyroid or liver function abnormalities, or serologic markers of

connective tissue disease (scleroderma and lupus), hepatitis, or human immunodeficiency virus.

Cardiac enzymes may be elevated in patients with right ventricular overdistension and ischemia. Troponin I leak due to acute right ventricular strain from pulmonary embolism has been described (21), and may predict mortality (22). B-type natriuretic peptide (BNP) is a prognostic indicator in patients with severe pulmonary hypertension (23). The utility of measuring BNP in critically ill patients with pulmonary hypertension is unclear, however. BNP levels may be elevated in critically ill surgical patients (24), patients with shock (25), or critically ill patients with cardiac dysfunction of any cause (26, 27). Although the diagnostic utility of BNP in renal insufficiency has been thought to be limited, recent literature (28) suggests that a plasma BNP of ≥ 150 pg/mL is a reliable marker of left ventricular overload and heart failure in patients with chronic renal failure. In patients with renal failure, a relative reduction in BNP after hemodialysis can be a valid indicator of improved left ventricular wall tension (29), but the utility of its measurement in patients with concomitant right ventricular dysfunction and critical illness remains questionable (30).

Electrocardiography is an insensitive measure of right ventricular hypertrophy, but the findings of right axis deviation, R/S wave >1 in V_1 with R wave >0.5 mV, and P pulmonale are more than 90% specific (31). Electrocardiography changes reflecting right ventricular abnormalities are significant predictors of mortality in patients with idiopathic PAH (32). Although these electrocardiography findings have not been used for prognosis in the ICU, they provide evidence of advanced disease that may be difficult to manage in critically ill patients. Electrocardiography scoring systems that correlate with the extent of perfusion defects in acute pulmonary embolism also have been developed (33), and may prove useful in the future to diagnose and stratify patients with pulmonary hypertension and right ventricular failure.

Plain chest radiography is of limited utility in diagnosing pulmonary hypertension in the ICU, but may help define an underlying cause. Typical findings of right ventricular hypertrophy, right atrial enlargement, and obscuring of the aortopulmonary window by enlarged pulmo-

nary arteries are less obvious on portable radiographs. Nonetheless, diffuse severe pulmonary parenchymal abnormalities may suggest an underlying cause of pulmonary hypertension. Computerized tomographic angiography, ventilation-perfusion scanning, or pulmonary angiography may identify thromboembolic disease as the cause of pulmonary hypertension (4).

Echocardiography is useful for diagnosing and determining the degree and significance of pulmonary hypertension (4). Echocardiography can noninvasively estimate right atrial and pulmonary arterial pressures, determine the degree of right ventricular dysfunction, and reveal potential causes of pulmonary hypertension such as left ventricular systolic or diastolic dysfunction, mitral stenosis or regurgitation, and certain intracardiac shunts. Although images may be suboptimal in critically ill patients because of limitations of patient positioning, interference by dressings, or positive pressure ventilation, a transthoracic echocardiogram should be obtained as a screening test (4). Echocardiographic signs of significant pulmonary hypertension include right ventricular dilation and hypertrophy, septal bowing into the left ventricle during late systole to early diastole (D-shaped left ventricle), right ventricular hypokinesis, tricuspid regurgitation, right atrial enlargement, and a dilated inferior vena cava (3, 34, 35). Increased right ventricular size and outflow impedance combined with reduced ejection fraction have been described in acute cor pulmonale. Demonstration of septal dyskinesia and right ventricular enlargement indicate right ventricular systolic and diastolic overload, respectively (34, 35).

In acute pulmonary embolism, McConnell and colleagues (36) also described a specific pattern of right ventricular dysfunction characterized by a severe hypokinesia of the right ventricular mid-free wall, with normal contractions of the apical segment. Echocardiographic predictors of poor outcomes in PAH include right atrial enlargement, septal bowing, and the development of a pericardial effusion (37).

Transesophageal echocardiography may be more sensitive than transthoracic echocardiography, especially in acute disease such as pulmonary embolism (38), and may provide clearer and more accurate information in critically ill patients (39).

Right heart or pulmonary artery (PA) catheterization is the gold standard for the diagnosis of pulmonary hypertension (3). In patients with significant PAH, the most useful information is obtained in the cardiac catheterization laboratory. Precise analysis of mixed venous oxygen saturations during insertion and passage of the PA catheter through the cardiac chambers can allow diagnosis of intracardiac shunts. A pulmonary capillary wedge pressure less than 15 mm Hg helps rule out left ventricular and pulmonary venous diseases (3). Observation of real-time mean PA pressure (mPAP), cardiac output, and PVR allows immediate evaluation of response to vasodilator therapy. Although the definition of a substantial response to therapy remains controversial, the most recent definition requires a reduction in mPAP of at least 10 mm Hg to ≤ 40 mm Hg with an increased or unchanged cardiac output (40). Because increased pulmonary arterial blood flow can elevate mPAP, documentation of the response to therapy also should include

the change in PVR. Regardless of the parameters used, the presence of vasoreactivity may suggest a better prognosis and ultimately can help determine medical therapy (41).

Despite current controversies regarding the utility of PA catheters in the ICU, hemodynamic data are valuable in the care of critically ill patients with pulmonary hypertension. In this setting, technical and interpretive limitations must be recognized. Severe tricuspid regurgitation and elevated PAP often make placing a PA catheter challenging, and may necessitate the use of fluoroscopy. Accurate determination of cardiac output by thermodilution may be limited in patients with tricuspid regurgitation or low cardiac output (42). The Fick method may be more accurate, but requires determination of oxygen consumption, which is challenging in critically ill patients. The superiority of thermodilution vs. the Fick method in critically ill patients remains controversial (43).

Complications of PA catheterization are particularly dangerous in patients with pulmonary hypertension and right ventricular strain. Tachyarrhythmias have potentially life-threatening consequences of decreased stroke volume due to shortened filling time, or deterioration into fatal arrhythmias. Obtaining a pulmonary capillary wedge pressure also may be difficult in patients with markedly elevated pulmonary pressures.

MANAGEMENT OF PULMONARY HYPERTENSION IN THE ICU

Overview

When managing a critically ill patient with pulmonary hypertension in the ICU, primary considerations include the diagnosis and treatment of specific causes of pulmonary hypertension, the application of PAH-specific therapies only when appropriate, and determination of the degree of right ventricular failure and its appropriate therapy (Fig. 3).

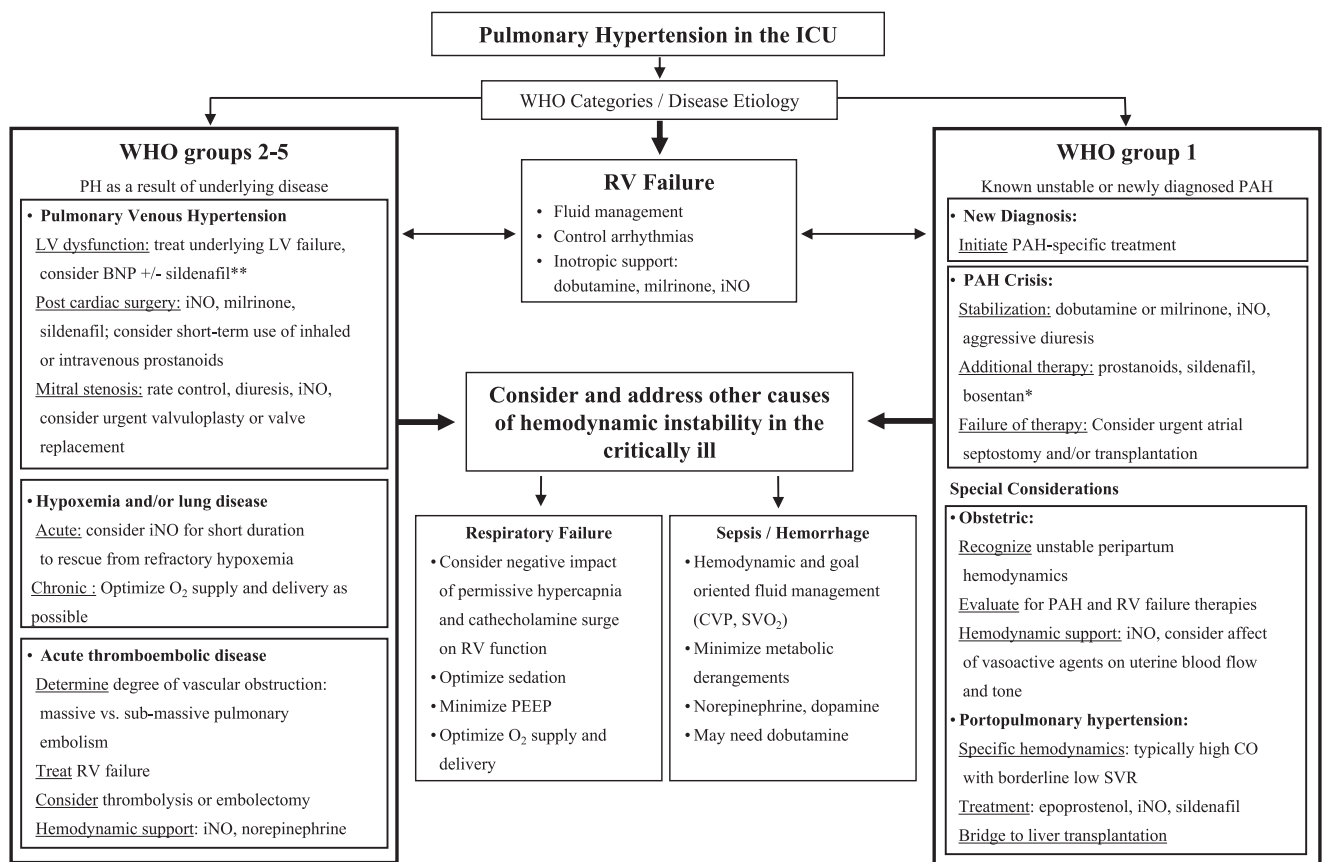


Figure 3. Suggested evaluation and treatment algorithm for pulmonary hypertension in the intensive care unit (ICU). WHO, World Health Organization; PH, pulmonary hypertension; RV, right ventricle; LV, left ventricle; PAH, pulmonary arterial hypertension; BNP, B-type natriuretic peptide; iNO, inhaled nitric oxide; CVP, central venous pressure; SVO₂, mixed venous oxygen saturation; CO, cardiac output; PEEP, positive end-expiratory pressure; SVR, systemic vascular resistance. *Bosentan initiation requires normal liver transaminases and may be associated with fluid retention and necessitate further diuresis. **Sildenafil is contraindicated in concomitant use with nitroglycerin because of its hypotensive potential.

The revised classification of pulmonary hypertension (Table 1) provides a framework for treatment of pulmonary hypertension patients in the ICU. Patients with PAH (World Health Organization group 1) can benefit from prostacyclin, sildenafil, or from long-term bosentan therapy, depending on the severity of their illness and functional classification. Patients with decompensated PAH often require an aggressive combination of therapies for right ventricular failure, including pulmonary vasodilators and inotropes. In patients with pulmonary venous hypertension (World Health Organization group 2), optimization of left-sided heart failure and valvular disease management is the most important facet of therapy. In patients with pulmonary hypertension secondary to various causes of parenchymal lung disease and/or hypoxemia, primary therapy consists of treating the underlying cause. Patients with pulmonary hypertension resulting from critical illness (Table 2) or chronic lung disease (44) are less likely to suffer from significant underlying pulmonary vascular disease, and their treatment should address the primary cause of their hemodynamic deterioration, such as sepsis or left ventricular dysfunction. These patients usually do not require treatment with pulmonary vasodilators. In patients with acute thromboembolic disease, therapy consists of anticoagula-

tion (45), thrombolysis, or thrombectomy (see section on pulmonary embolism).

Aggressive fluid balance management is critical in patients with decompensated pulmonary hypertension and right ventricular failure. Hypovolemia and hypervolemia both can lead to suboptimal preload and decreased cardiac output. Maintenance of sinus rhythm and atrioventricular synchrony is especially important in the presence of right ventricular dysfunction. For example, atrial fibrillation or complete atrioventricular block are poorly tolerated in patients with acute pulmonary emboli or in chronic right ventricular failure (46). In the hemodynamically unstable patient, initiation of inotropic therapy may be necessary. Dobutamine is the inotrope that has been the most extensively studied in the context of acute right-sided failure (see below), but other agents may be beneficial. In refractory right ventricular failure, early consideration of atrial septostomy (see below), heart or heart-lung transplantation, or right ventricular assist-device placement may be life-saving (47).

Effects of Mechanical Ventilation

In patients with pulmonary hypertension and respiratory failure, mechanical ventilation may have untoward hemodynamic effects. Increases in lung volume and decreases in functional residual capacity can increase PVR and right ventricular afterload (48). In patients with normal right ventricular function, transient increases in PVR are inconsequential. However, in patients with preexisting or impending right ventricular failure, lung hyperinflation and either inadequate or excessive positive end-expiratory pressure can fatally reduce cardiac output (48).

In a study of seven mechanically ventilated patients with acute lung injury and ARDS, six developed significant tricuspid regurgitation, elevated PAP, and increased pulmonary capillary wedge pressure during incremental increases in positive end-expiratory pressure from 5 mm Hg to 20 mm Hg (49). The elevated PAP correlated directly with increased right atrial pressure and PVR. Other investigators demonstrated increased right ventricular outflow impedance in mechanically ventilated patients as tidal volume was progressively increased, an ef-

fect that was ameliorated with the application of low levels of positive end-expiratory pressure between 3 cm H₂O and 8 cm H₂O (50). These data suggest that the optimal ventilator management of patients with pulmonary hypertension may be with low tidal volumes and relatively low positive end-expiratory pressure. This strategy of low tidal volume ventilation is similar to the strategy used to ventilate patients with ARDS, but care should be taken to avoid permissive hypercapnia, which may have untoward hemodynamic effects (51). A study of 18 patients after coronary artery bypass graft surgery demonstrated that hypercapnia increased PVR by 54% and mPAP by approximately 30% (52). Whether these effects are mediated by hypercapnia itself or by acidosis remains unclear (53).

Pharmacologic Therapy of Pulmonary Hypertension

Vasopressors and Inotropes. Hemodynamic goals in patients with right ventricular failure due to pulmonary hypertension are to reduce PVR, augment cardiac output, and resolve systemic hypotension while avoiding tachyarrhythmias. Most traditional vasopressors and inotropes are suboptimal in reducing pulmonary vascular resistance. Only a few small human studies address hemodynamic support in patients with PAH, right ventricular failure, and hypotension, and most of the common vasopressors and inotropes have not been studied. Animal studies predominately employ models of acute pulmonary hypertension and right ventricular failure, and may not be applicable to patients with longstanding PAH and altered right ventricular mechanics. The use of vasopressors and inotropes in patients with PAH must therefore be guided by knowledge of their effects on PVR and cardiac output, and must be individualized based on patient response. In many cases, combination therapy is required. The following discussion attempts to list agents in order of usefulness in treating pulmonary hypertension and associated right ventricular failure.

Dobutamine. Dobutamine is an inotrope that acts primarily through β_1 -adrenergic receptors to augment myocardial contractility and reduce left ventricular afterload (54). In animal models of acute pulmonary hypertension,

Table 2. Common causes of pulmonary hypertension in the intensive care unit

Hypoxemia/parenchymal lung disease
Acute respiratory distress syndrome
Pulmonary embolism
Interstitial lung disease
Obstructive sleep apnea
Chronic obstructive pulmonary disease
Left heart disease
Acute myocardial infarction
Valvular disease (mitral regurgitation/mitral stenosis)
Severe diastolic dysfunction
Cardiomyopathy
Postoperative states
Coronary artery bypass grafting
Cardiac transplantation
Lung/heart-lung transplantation
Pneumectomy
Thromboembolic lung disease
Pulmonary embolism
Deterioration of chronic pulmonary arterial hypertension
Fluid overloaded state
Arrhythmias
Pulmonary embolism
Acute on chronic pulmonary hypertension
Medication withdrawal

dobutamine in doses up to 5 $\mu\text{g}/\text{kg}$ per min significantly decreased PVR while slightly increasing cardiac output (55, 56). However, at doses of 5–10 $\mu\text{g}/\text{kg}$ per min, dobutamine caused significant tachycardia without improving pulmonary vascular resistance. In a canine model of acute right ventricular failure, dobutamine was superior to norepinephrine in promoting right ventricular-pulmonary artery coupling, a process that reflects improved right ventricular function by optimizing pulmonary vasodilation (55), probably because of superior inotropic properties (57). When combined with inhaled nitric oxide in both animal and human studies of acute and chronic pulmonary hypertension, dobutamine improved cardiac index, decreased PVR indices (56, 58), and significantly increased $\text{PaO}_2/\text{FiO}_2$ (58).

These studies suggest that dobutamine doses in both acute and chronic pulmonary hypertension should be maintained at less than 5 $\mu\text{g}/\text{kg}$ per min, and should be combined with pulmonary vasodilators such as inhaled nitric oxide when possible. However, dobutamine may cause systemic hypotension in some patients because of its peripheral β -adrenergic effects and may necessitate the use of norepinephrine or a peripheral vasoconstrictor.

Norepinephrine. Norepinephrine stimulates α_1 - and β_1 -adrenergic receptors. When used in animal and human studies of both acute and chronic pulmonary hypertension, it has been shown to increase mPAP and PVR (59, 60). However, unlike phenylephrine, norepinephrine maintained or improved cardiac output in patients with pulmonary hypertension. Selective infusion of norepinephrine into the left atrium, combined with prostaglandin E_1 administration into the right atrium, has been useful in weaning patients with acute pulmonary hypertension from cardiopulmonary bypass (61). There are no data that such selective infusion is beneficial in other patient populations. Unlike dobutamine, norepinephrine has vasoconstrictive effects that are much more pronounced than the chronotropic and inotropic effects (55). Although norepinephrine may be useful in hypotensive patients and cause less tachycardia, dobutamine remains a superior choice in the setting of pulmonary hypertension and right ventricular failure.

Dopamine. Dopamine is an adrenergic and dopaminergic agonist that increases

blood pressure and cardiac output (62). One animal study suggests that the use of dopamine in acute embolic pulmonary hypertension augments cardiac output and reduces PVR (63). A human study, however, failed to demonstrate a consistent reduction in PVR (64). In addition, the augmented cardiac output comes at the price of significant tachycardia that may decrease left ventricular preload and worsen demand ischemia.

Phenylephrine. Phenylephrine is an α_1 -adrenergic agent and a powerful arteriolar vasoconstrictor that can improve right ventricular coronary perfusion (59). However, phenylephrine increases mPAP and PVR and decreases cardiac output, thus worsening right ventricular pressure overload in patients with chronic pulmonary hypertension (59, 65). Phenylephrine also may cause reflex bradycardia (66), which may be detrimental to right ventricular hemodynamics. In patients with significant pulmonary hypertension, phenylephrine usually should be avoided.

Isoproterenol. Isoproterenol is primarily a β_1 - and β_2 -adrenergic agonist that has historically been used to treat pulmonary hypertension during surgery. Because it is a stronger chronotropic agent than dobutamine, the use of isoproterenol is associated with significant tachyarrhythmias. Although it improves cardiac output and PVR (60), the utility of isoproterenol in animal models of acute pulmonary hypertension has been limited by the induction of arrhythmias and the lack of effect on PAP (67).

Epinephrine. Although commonly used to improve cardiac output and increase systemic vascular resistance in hypotensive patients in the ICU, epinephrine, a potent α - and β -adrenergic agent, has not been studied in the setting of pulmonary hypertension.

Vasopressin. Vasopressin is a weak nonadrenergic vasopressor that is believed to be a systemic vasoconstrictor and a selective pulmonary vasodilator (68–70). However, in an animal model of acute pulmonary hypertension, vasopressin at an average dose of 1.16 units/kg per hr increased mPAP and PVR and decreased cardiac output (71). This suggests that vasopressin in high doses should be avoided in patients with pulmonary hypertension. On the other hand, recent data suggest that the optimal dose of vasopressin in shock is much lower than used in the aforementioned study (72). Whether low-dose vasopressin is

useful in the management of pulmonary hypertension in the ICU requires further investigation.

Pulmonary Vasodilators

Pulmonary vasodilators can be classified into two main categories: those that increase production of cyclic guanosine monophosphate and cyclic adenosine monophosphate, such as nitric oxide and prostanoids, respectively; and those that decrease the breakdown of cyclic guanosine monophosphate, such as sildenafil and zaprinast (5, 6), and of cyclic adenosine monophosphate, such as milrinone.

Nitric Oxide. Nitric oxide is a potent vasodilator that, when inhaled, dilates pulmonary vasculature in ventilated lung units, thereby improving oxygenation, reversing hypoxic pulmonary vasoconstriction, and reducing PAP. Nitric oxide is quickly inactivated by reaction with hemoglobin in the pulmonary capillaries, and has no systemic vasodilatory effects. Inhaled nitric oxide has been studied in pulmonary hypertension of various etiologies (73–76). Several studies have focused on inhaled nitric oxide therapy in adults with pulmonary hypertension and ARDS (73, 77, 78). Although ARDS patients without sepsis initially improve oxygenation with inhaled nitric oxide, there is no evidence that outcomes are improved (79). In chronic PAH, inhaled nitric oxide significantly decreases mPAP and PVR without affecting systemic vascular resistance or cardiac output (58, 80). Of 26 patients diagnosed in an ICU with acute right heart syndrome, 14 had significant hemodynamic improvement when treated with a mean concentration of 35 ppm of inhaled nitric oxide. In these patients there was a 38% reduction in PVR, 36% increase in CO, and a 28% increase in $\text{PaO}_2/\text{FiO}_2$ (81).

The use of nitric oxide is not without potential problems, however. Although uncommon, the development of methemoglobinemia may limit its use, especially with prolonged administration at higher concentrations (82). Also, the interaction of nitric oxide and high concentrations of oxygen produces NO_2 , a significant oxidant (83). Abrupt withdrawal of nitric oxide has been associated with rebound pulmonary hypertension and hemodynamic collapse in up to 48% of patients evaluated (81, 84). In spite of its limitations, inhaled nitric oxide is a useful agent to treat pulmonary hypertension, particularly in combination with

other agents such as dobutamine or milrinone (see below).

Prostaglandins. Early studies of intravenous prostaglandin E₁ and prostacyclin (or epoprostenol) in an animal model of acute embolic pulmonary hypertension showed significant reductions in PVR and mPAP, as well as augmentation of cardiac output (80). Prostaglandin E₁ and prostacyclin were more effective than isoproterenol and nifedipine, with nearly 40% reduction in PVR and approximately 35% improvement in cardiac output. More recent studies have demonstrated the efficacy of both inhaled and intravenous prostacyclin (85–88). In a retrospective study of 33 ICU patients with hypoxemia and pulmonary hypertension from cardiac and noncardiac causes, inhaled prostacyclin improved mPAP and hypoxemia (89). Other studies and case reports have demonstrated the utility of inhaled prostacyclin and of the prostacyclin analog, iloprost, in reducing PAP and improving cardiac output (90–93), although prospective studies in critically ill patients with pulmonary hypertension are lacking. Subcutaneous or intravenous treprostinil, another prostacyclin analog, is also an effective treatment for pulmonary hypertension (6), but its long half life (3–4 hrs) makes it less appropriate in hemodynamically unstable patients in the ICU.

In patients with PAH and right ventricular failure, chronic therapy with intravenous epoprostenol may be life-saving. Epoprostenol has an elimination half-life of 3–6 mins and is typically started at a dose of 1–2 ng/kg per min, titrated upward at a rate of 0.5–1.0 ng/kg per min at intervals of 15–30 mins or more. An increase in cardiac output with a decrease in PAP and PVR is considered a favorable response.

The use of epoprostenol to reduce PA pressures acutely is limited by dose-dependent systemic side effects (88), particularly systemic hypotension. In conscious patients, headache, nausea, vomiting, and diarrhea also may limit rapid titration of epoprostenol. In patients treated chronically with epoprostenol, abrupt discontinuation of the infusion may cause severe rebound pulmonary hypertension and death within minutes (40).

Milrinone. Milrinone is a selective phosphodiesterase-3 inhibitor with inotropic and vasodilatory effects. In animal models of both acute and chronic pulmonary hypertension, milrinone significantly reduced PVR and improved right ventricular function (94, 95). In combi-

nation with inhaled nitric oxide, milrinone produces selective and additive pulmonary vasodilatation in pediatric patients after repair of congenital heart defects (96), and after cardiac surgery in animal studies (94). However, compared with zaprinast, a selective phosphodiesterase-5 inhibitor, milrinone has inferior pulmonary vasodilatory effects and more pronounced lowering of systemic arterial pressures (97). Thus, based on animal data and limited human data, selective phosphodiesterase-5 inhibition may be more beneficial than milrinone. Milrinone may have some utility in the treatment of hemodynamic instability in patients with pulmonary hypertension, although systemic hypotension often limits its use. Further studies are needed to verify the effects of milrinone in patients with pulmonary hypertension.

Sildenafil. Sildenafil is a specific phosphodiesterase-5 inhibitor with acute and chronic hemodynamic effects in patients with pulmonary hypertension (98–100), and recently has been approved for the treatment of PAH. However, there are only case reports or small case series describing its use in critically ill patients. A retrospective case review of eight adults with pulmonary hypertension after mitral valve repair or placement of a left ventricular assist device showed that sildenafil significantly reduced mPAP and reduced PVR with only a minimal drop in mean arterial pressure, thus facilitating weaning of inhaled and intravenous pulmonary vasodilators (101).

In stable patients, sildenafil alone or in combination with inhaled nitric oxide or epoprostenol reduces mPAP and PVR and increases cardiac output (102, 103). In patients with idiopathic PAH, sildenafil also can significantly improve cardiac output (100). Furthermore, limited human and animal data suggest that sildenafil and zaprinast may augment and maintain the effects of inhaled nitric oxide (98, 104–108) and iloprost (109) and minimize rebound pulmonary hypertension after withdrawal of these agents (110, 111). Additionally, some authors speculate that sildenafil may improve pulmonary hemodynamics and myocardial perfusion after coronary artery bypass graft surgery (112).

The hemodynamic effects of sildenafil start within 15 mins of administration and last up to several hours, although peak hemodynamic effects are seen within 30–60 mins. The relatively rapid onset of action, its diminution during

3–4 hrs, and the accompanying systemic hypotension suggest caution in critically ill patients. Sildenafil is contraindicated in patients receiving nitrates because of the potential for severe systemic hypotension.

Nesiritide. Recombinant human BNP (nesiritide) is a recently developed drug that increases cyclic guanosine monophosphate and dilates vascular smooth muscle. Its vasodilatory effect reduces right and left ventricular preload and may benefit patients with pulmonary hypertension resulting from biventricular failure (113). In a recent small study of patients with PAH (19), BNP infusion alone did not significantly improve pulmonary hemodynamics, but was safe and augmented the vasodilatory effects of sildenafil. However, others have shown that the reduction of systemic vascular resistance by nesiritide may cause detrimental systemic hypotension in patients with PAH and isolated right ventricular failure (114). Currently, therefore, the use of nesiritide should be limited to patients with biventricular failure who are not hypotensive.

Miscellaneous Therapy

Oxygen. Oxygen inhalation has been shown to reduce PA pressure and improve cardiac output in patients with pulmonary hypertension, regardless of the underlying cause (115). In addition, hypoxic pulmonary vasoconstriction may contribute to pulmonary hypertension in critically ill patients (116). Thus, supplemental oxygen should not be overlooked as a key component of pulmonary hypertension therapy in the ICU.

Diuretics. Diuretics have long been conventional therapy for pulmonary hypertension, whether caused by pulmonary vascular disease or left ventricular failure. Although human studies of diuretic use in pulmonary hypertension are lacking, there is evidence in the setting of exercise-induced pulmonary hypertension in race horses (117). The goal of diuretic use is to decrease volume load on the distended, failing right ventricle in advanced pulmonary hypertension without compromising preload. Optimization of diuresis in this setting is complex and should be adjusted according to hemodynamic response.

Digoxin. The use of digoxin in patients with pulmonary hypertension and right ventricular dysfunction is controversial. In a study of the short-term effects of

digoxin in 17 patients with severe primary pulmonary hypertension (118), cardiac index improved mildly and catecholamine levels decreased, but PVR did not change and mPAP increased. Nonetheless, because there are more effective drugs to treat right ventricular failure and supraventricular tachyarrhythmias, digoxin is not commonly used in the ICU for this purpose.

Calcium Channel Blockers. There are no studies of calcium channel blockers in critically ill patients with PAH, and because of their negative inotropic effects they may precipitate fatal worsening of right ventricular failure. In chronic PAH, calcium channel blocker use should be limited to stable patients with a demonstrated response to acute vasodilator challenge (40). Cautious use of calcium channel blockers may help control the heart rate in patients with pulmonary hypertension and heart failure secondary to mitral stenosis and certain tachyarrhythmias, although agents with the greatest negative inotropic effects (such as verapamil) should be avoided.

Anticoagulants. Anticoagulation is considered the standard of care in patients with idiopathic PAH. However, aside from recent guidelines established for the treatment of acute and chronic thromboembolic diseases (119), data for anticoagulation of patients with pulmonary hypertension in the ICU are lacking. Although anticoagulants may play a role in critical illnesses such as sepsis and acute lung injury (120, 121), their use in critically ill patients with pulmonary hypertension has not been examined.

Surgical Therapy

Atrial Septostomy. The observations of improved survival patients with pulmonary hypertension and a patent foramen ovale (122), and patients with congenital heart diseases and Eisenmenger's physiology (123, 124), suggested that creation of an atrial septal shunt would improve survival in patients with pulmonary hypertension. Since the first palliative atrial septostomy in 1983, several studies have evaluated atrial septostomy for pulmonary hypertension (125, 126), or as a bridge to transplantation (127). Still controversial in the nonurgent setting, atrial septostomy has a very high associated morbidity and mortality in critically ill patients with severe right ventricular failure (125–127). It should not be performed in patients with mean right atrial

pressures of >20 mm Hg, significant hypoxemia, and a PVR index >4400 dynes sec/cm⁵ per m² (47, 127).

MISCELLANEOUS CAUSES OF PULMONARY HYPERTENSION

Some causes of pulmonary hypertension and hemodynamic instability encountered in the ICU require urgent therapy of the underlying disorder. Even in these cases, the aforementioned drugs are sometimes useful in the short term.

Pulmonary Embolism

Acute, massive pulmonary embolism may cause acute pulmonary hypertension and right ventricular failure (81) requiring inotropic support. In a large multicenter study of pulmonary embolism, hospital mortality in patients presenting with hemodynamic instability was 31% (128). Therapy for acute massive pulmonary embolism with associated hemodynamic instability or shock thus aims to urgently relieve mechanical obstruction of the pulmonary vasculature caused by thrombus and intense vasoconstriction. When pulmonary embolism is associated with hemodynamic instability, urgent pharmacologic thrombolysis is recommended unless contraindicated, and is associated with more rapid resolution of thrombus than anticoagulation alone, although the mortality benefit is unclear (119). If thrombolysis fails or is contraindicated, surgical embolectomy is indicated in centers where an experienced cardiac surgical team is available (119). Percutaneous mechanical clot disruption also has been reported, but data comparing outcomes to pharmacologic thrombolysis or surgical thrombectomy are limited (129, 130). In submassive pulmonary embolism associated with echocardiographic evidence of right ventricular strain but without hemodynamic instability, thrombolysis is recommended by some, although this remains controversial (131).

Data supporting specific pharmacologic therapy of acute pulmonary embolism with right ventricular failure are sparse. Animal studies suggest that norepinephrine may be useful to treat hypotension in acute pulmonary embolism (132, 133), but data in humans are lacking. Inhaled nitric oxide also may improve hemodynamics in acute pulmonary

embolism (134) and is being used increasingly in many centers.

Mitral Stenosis

Mitral stenosis increases left atrial and pulmonary venous pressures, and may eventually lead to pulmonary hypertension. Diuretics are the mainstay of medical management and can improve cardiac output. Rate control also is crucial, and may be achieved with diltiazem. Concomitant atrial fibrillation and right ventricular failure may be treated with β -blockers. Although inhaled nitric oxide can be useful for short-term management (135), valvuloplasty or valve replacement are the definitive therapies.

Chronic Liver Disease

Portopulmonary hypertension is an uncommon cause of pulmonary hypertension in the ICU, and is a manifestation of chronic liver disease. Acute liver failure rarely leads to portopulmonary hypertension, but congestive hepatopathy is frequently noted as a consequence of right heart failure. Patients with portopulmonary hypertension may have higher cardiac output and lower systemic vascular resistance indices than patients with idiopathic PAH (136). Although treating patients with portopulmonary hypertension may be particularly challenging because of preexisting systemic hypotension, limited data suggest that the therapy is essentially the same as in patients with decompensated pulmonary hypertension of other etiologies (137).

Portopulmonary hypertension is often asymptomatic and is discovered incidentally when patients with end-stage liver disease undergo evaluation for liver transplantation. Case reports and case series most commonly describe treating portopulmonary hypertension with intravenous epoprostenol (138, 139) or sildenafil (140, 141), often as a bridge to liver transplantation. There are no studies of therapy for critically ill patients with portopulmonary hypertension either before or after liver transplantation.

Portopulmonary hypertension is most problematic in the perioperative period surrounding liver transplantation. Some degree of pulmonary hypertension exists in up to 31% of liver transplant recipients (142), but severe pulmonary hypertension (mPAP >45 mm Hg) is considered by most to be a contraindication to liver transplantation. The mortality rate after

transplantation in patients with portopulmonary hypertension is 36% (102), and in patients with severe pulmonary hypertension is 50% to 100%, predominantly due to right heart failure (142). Because of these poor outcomes, the number of patients with moderate to severe portopulmonary hypertension who have been transplanted is small. As a result, there are only rare case reports of the use of epoprostenol or inhaled nitric oxide after liver transplantation (103, 143), and no prospective studies.

Postoperative Pulmonary Hypertension

Cardiac and thoracic surgery may be complicated by postoperative pulmonary hypertension. Pulmonary hypertension is recognized as a major risk factor for morbidity and mortality in cardiothoracic surgery (144). Although the etiology of postoperative pulmonary hypertension is unclear, pulmonary parenchymal and endothelial injury due to cardiopulmonary bypass (145–147) and ischemia-reperfusion injury (148) have been implicated after cardiac surgery, cardiac or lung transplantation, and pneumonectomy. A variety of approaches to the therapy of pulmonary hypertension and right ventricular failure have been used in patients who have undergone cardiac or thoracic surgery or transplantation, and combined therapy is commonly used.

In small series, both inhaled prostacyclin and nitric oxide have been shown to be valuable in treating pulmonary hypertension after mitral valve replacement (149, 150) and other types of cardiac surgery requiring cardiopulmonary bypass (148). Pulmonary hypertension in the early postoperative period after cardiac transplantation may be particularly difficult to manage, and approaches such as the use of inhaled nitric oxide, prostacyclin, and prostaglandin E₁ have been used in small case series (151). In patients with pulmonary hypertension related to low cardiac output following cardiac surgery, dobutamine and milrinone may be useful (146), but may cause hypotension requiring the concomitant use of vasopressor therapy.

In spite of a paucity of prospective data, inhaled nitric oxide is being increasingly used in critically ill patients and is associated with improved outcomes in postoperative patients when compared with critically ill medical patients. A retrospective study of inhaled nitric oxide

compared 317 postoperative patients with 59 medical patients and found the highest survival rates in patients who had received heart or lung transplants, and the lowest survival rates in medical patients (152). The vast majority of the postoperative patients in this study received nitric oxide for severe pulmonary hypertension or right ventricular failure after cardiac transplantation, lung transplantation, cardiac surgery, or ventricular assist device placement. After cardiac transplantation, the use of inhaled nitric oxide is associated with improved PVR and right ventricular function and a trend toward improved survival when compared with historic controls (153). Treatment of postcardiac surgery pulmonary hypertension with inhaled nitric oxide, compared with milrinone, also has been shown to cause less heart rate elevation, improved right ventricular ejection fraction, and a decreased need for vasopressor therapy (154).

In a group of patients who were difficult to wean from cardiopulmonary bypass because of isolated right ventricular failure, inhaled iloprost was successfully used to reduce pulmonary vascular resistance (155). Inhaled iloprost also was shown to be effective in treating pulmonary hypertension and acute right ventricular dysfunction in another small perioperative study of eight cardiac transplant patients (156).

Sildenafil also has been cited in case reports in combination with inhaled nitric oxide (157) or as an aid to weaning inhaled nitric oxide after left ventricular assist-device placement (158) or cardiac transplantation complicated by severe pulmonary hypertension (159). It also was useful in a series of eight patients to facilitate weaning from intravenous vasodilators after mitral valve surgery or left ventricular assist-device placement (101), but no prospective studies of its use in the ICU have been published.

Pulmonary Veno-Occlusive Disease

Pulmonary veno-occlusive disease is a rare cause of pulmonary hypertension, accounting for only about 10% of idiopathic cases (160). Pulmonary veno-occlusive disease is characterized pathologically by fibrotic changes in small pulmonary veins and by dilation of pulmonary and pleural lymphatics. Chest radiographs may show Kerley B lines (161); computed tomography reveals ground

glass opacities and thickened septal lines (162). In spite of its rarity, pulmonary veno-occlusive disease deserves mention, because pulmonary vasodilator therapy typically used for PAH may cause life-threatening pulmonary edema. Nonetheless, options for treatment are limited, and a cautious trial of short-acting pulmonary vasodilators is reasonable (163).

Pulmonary Hypertension and Pregnancy

The mortality rate in women with pulmonary hypertension who become pregnant ranges from 30% to 56%, depending on the underlying cause (162). Pregnancy causes an increase in circulating blood volume by nearly 50%, with a concomitant increase in cardiac output and decreased systemic vascular resistance, as well as an increase in oxygen consumption. After delivery, circulating blood volume increases further and venous return increases as the uterus involutes, worsening right ventricular strain. Hospitalization is recommended at approximately 20 wks and treatment to avoid volume overload is an important part of management. Epoprostenol is often necessary, and inhaled nitric oxide has been used in the immediate peripartum period. In animals studies, inhaled iloprost has been linked to teratogenicity and fetal wastage (162) and bosentan can be teratogenic (163).

CONCLUSIONS

Pulmonary hypertension and concomitant right ventricular failure present a particular therapeutic challenge in hemodynamically unstable patients in the ICU. Typical therapies such as volume resuscitation and mechanical ventilation may worsen hemodynamics and further complicate management. To determine appropriate therapy, the approach to patients with pulmonary hypertension in the ICU must begin with identification of the underlying cause. Patients with decompensated PAH, including patients with preexisting PAH or with pulmonary hypertension associated with cardiac or thoracic transplant surgery, require therapy for right ventricular failure. Hemodynamic collapse caused by acute massive pulmonary embolism requires urgent relief of vascular obstruction. Patients with pulmonary hypertension resulting from critical illness or chronic lung disease are

unlikely to suffer from underlying pulmonary vascular disease, and their treatment should address the primary cause of their hemodynamic deterioration. Although very few human studies have addressed the use of vasopressors and pulmonary vasodilators in critically ill, hypotensive patients with chronic PAH and right ventricular failure, the use of dobutamine, inhaled nitric oxide, and intravenous prostacyclin have the greatest support in the literature. The use of other agents should be guided by an understanding of their effects on the right ventricle and pulmonary circulation, and by the comorbid conditions of the patients being treated.

REFERENCES

1. Hoepfer MM, Galiè N, Murali S, et al: Outcome after cardiopulmonary resuscitation in patients with pulmonary arterial hypertension. *Am J Respir Crit Care Med* 2002; 165:341–344
2. Rubin LJ: Diagnosis and management of pulmonary arterial hypertension: ACCP evidence-based clinical practice guidelines. *Chest* 2004; 126:7S–10S
3. Chemla D, Castelain V, Herve P, et al: Haemodynamic evaluation of pulmonary hypertension. *Eur Respir J* 2002; 20:1314–1331
4. Barst RJ, McGoon M, Torbicki A, et al: Diagnosis and differential assessment of pulmonary arterial hypertension. *J Am Coll Cardiol* 2004; 43:40S–47S
5. Humbert M, Morrell NW, Archer SL, et al: Cellular and molecular pathobiology of pulmonary arterial hypertension. *J Am Coll Cardiol* 2004; 43:13S–24S
6. Humbert M, Sitbon O, Simonneau G: Therapies for pulmonary arterial hypertension. *N Engl J Med* 2004; 351:1425–1436
7. Weitzenblum E, Chaouat A: Pulmonary hypertension due to chronic hypoxic lung disease. In: Peacock AJ, Rubin LJ (Eds). *Pulmonary Circulation: Diseases and Their Treatment*. Second Edition. New York, NY, Oxford University Press, 2004, pp 376
8. Ishikawa S, Miyauchi T, Sakai S, et al: Elevated levels of plasma endothelin-1 in young patients with pulmonary hypertension caused by congenital heart disease are decreased after successful surgical repair. *J Thorac Cardiovasc Surg* 1995; 110: 271–273
9. Stewart DJ, Levy RD, Cernacek P, et al: Increased plasma endothelin-1 in pulmonary hypertension: Marker or mediator of disease? *Ann Intern Med* 1991; 114: 464–469
10. Kim H, Yung GL, Marsh JJ, et al: Endothelin mediates pulmonary vascular remodeling in a canine model of chronic embolic pulmonary hypertension. *Eur Respir J* 2000; 15:640–648
11. Herve P, Launay JM, Scrobohaci ML, et al: Increased plasma serotonin in primary pulmonary hypertension. *Am J Med* 1995; 99: 249–254
12. Egermayer P, Town GI, Peacock AJ: Role of serotonin in the pathogenesis of acute and chronic pulmonary hypertension. *Thorax* 1999; 54:161–168
13. Abenheim L, Moride Y, Brenot F, et al: Appetite-suppressant drugs and the risk of primary pulmonary hypertension. International Primary Pulmonary Hypertension Study Group. *N Engl J Med* 1996; 335: 609–616
14. Machado RD, Koehler R, Glissmeyer E, et al: Genetic association of the serotonin transporter in pulmonary arterial hypertension. *Am J Resp Crit Care Med* 2006; 173: 793–797
15. Nath J, Foster E, Heidenreich PA: Impact of tricuspid regurgitation on long-term survival. *J Am Coll Cardiol* 2004; 43:405–409
16. Chin KM, Kim NH, Rubin LJ: The right ventricle in pulmonary hypertension. *Coron Artery Dis* 2005; 16:13–18
17. Dell'Italia LJ: The right ventricle: Anatomy, physiology, and clinical importance. *Curr Probl Cardiol* 1991; 16:653–720
18. Charloux A, Chaouat A, Piquard F, et al: Renal hyporesponsiveness to brain natriuretic peptide: Both generation and renal activity of cGMP are decreased in patients with pulmonary hypertension. *Peptides* 2006; 27:2993–2999
19. Klinger JR, Thaker S, Houtchens J, et al: Pulmonary hemodynamic responses to brain natriuretic peptide and sildenafil in patients with pulmonary arterial hypertension. *Chest* 2006; 129:417–425
20. Bates B, Bickley LS, Hoekelman RA: A guide to physical examination and history taking, Sixth Edition. Philadelphia, Lippincott; 1995
21. Mehta NJ, Jani K, Khan IA: Clinical usefulness and prognostic value of elevated cardiac troponin I levels in acute pulmonary embolism. *Am Heart J* 2003; 145: 821–825
22. La Vecchia L, Ottani F, Favero L, et al: Increased cardiac troponin I on admission predicts in-hospital mortality in acute pulmonary embolism. *Heart* 2004; 90:633–637
23. Leuchte HH, Holzapfel M, Baumgartner RA, et al: Clinical significance of brain natriuretic peptide in primary pulmonary hypertension. *J Am Coll Cardiol* 2004; 43: 764–770
24. Berendes E, Van Aken H, Rauffhake C, et al: Differential secretion of atrial and brain natriuretic peptide in critically ill patients. *Anesth Analg* 2001; 93:676–682
25. Tung RH, Garcia C, Morss AM, et al: Utility of B-type natriuretic peptide for the evaluation of intensive care unit shock. *Crit Care Med* 2004; 32:1643–1647
26. McLean AS, Huang SJ, Nalos M, et al: The confounding effects of age, gender, serum creatinine, and electrolyte concentrations on plasma B-type natriuretic peptide concentrations in critically ill patients. *Crit Care Med* 2003; 31:2611–2618
27. McLean AS, Tang B, Nalos M, et al: Increased B-type natriuretic peptide (BNP) level is a strong predictor for cardiac dysfunction in intensive care unit patients. *Anaesth Intensive Care* 2003; 31:21–27
28. Takami Y, Horio T, Iwashima Y, et al: Diagnostic and prognostic value of plasma brain natriuretic peptide in non-dialysis-dependent CRF. *Am J Kidney Dis* 2004; 44:420–428
29. McCullough PA, Sandberg KR: B-type natriuretic peptide and renal disease. *Heart Fail Rev* 2003; 8:355–358
30. Maeder M, Fehr T, Rickli H, et al: Sepsis-associated myocardial dysfunction: Diagnostic and prognostic impact of cardiac troponins and natriuretic peptides. *Chest* 2006; 129:1349–1366
31. Murphy ML, Thenabadu PN, de Soyza N, et al: Reevaluation of electrocardiographic criteria for left, right, and combined cardiac ventricular hypertrophy. *Am J Cardiol* 1984; 53:1140–1147
32. Bossone E, Paciocco G, Iarussi D, et al: The prognostic role of the ECG in primary pulmonary hypertension. *Chest* 2002; 121: 513–518
33. Iles S, Le Heron CJ, Davies G, et al: ECG score predicts those with the greatest percentage of perfusion defects due to acute pulmonary thromboembolic disease. *Chest* 2004; 125:1651–1656
34. Vieillard-Baron A, Prin S, Chergui K, et al: Echo-Doppler demonstration of acute cor pulmonale at the bedside in the medical intensive care unit. *Am J Respir Crit Care Med* 2002; 166:1310–1319
35. Jardin F, Vieillard-Baron A: Monitoring of right-sided heart function. *Curr Opin Crit Care* 2005; 11:271–279
36. McConnell MV, Solomon SD, Rayan ME, et al: Regional right ventricular dysfunction detected by echocardiography in acute pulmonary embolism. *Am J Cardiol* 1996; 78: 469–473
37. Raymond RJ, Hinderliter AL, Willis PW, et al: Echocardiographic predictors of adverse outcomes in primary pulmonary hypertension. *J Am Coll Cardiol* 2002; 39:1214–1219
38. Daniels LB, Krummen DE, Blanchard DG: Echocardiography in pulmonary vascular disease. *Cardiol Clin* 2004; 22:383–399
39. Karski JM: Transesophageal echocardiography in the intensive care unit. *Semin Cardiothorac Vasc Anesth* 2006; 10:162–166
40. Badesch DB, Abman SH, Ahearn GS, et al: Medical therapy for pulmonary arterial hypertension: ACCP evidence-based clinical practice guidelines. *Chest* 2004; 126: 35S–62S
41. McLaughlin VV, Presberg KW, Doyle RL, et al: Prognosis of pulmonary arterial hypertension: ACCP evidence-based clinical practice guidelines. *Chest* 2004; 126:78S–92S

42. Cigarroa RG, Lange RA, Williams RH, et al: Underestimation of cardiac output by thermodilution in patients with tricuspid regurgitation. *Am J Med* 1989; 86:417–420
43. Caruso LJ, Layon AJ, Gabrielli A: What is the best way to measure cardiac output? Who cares, anyway? *Chest* 2002; 122: 771–774
44. Thabut G, Dauriat G, Stern JB, et al: Pulmonary hemodynamics in advanced COPD candidates for lung volume reduction surgery or lung transplantation. *Chest* 2005; 127:1531–1536
45. Chin KM, Kim NH, Rubin LJ: The right ventricle in pulmonary hypertension. *Coron Artery Dis* 2005; 16:13–18
46. Goldstein JA, Harada A, Yagi Y, et al: Hemodynamic importance of systolic ventricular interaction, augmented right atrial contractility, and atrioventricular synchrony in acute right ventricular dysfunction. *J Am Coll Cardiol* 1990; 16:181–189
47. Olsson JK, Zamanian RT, Feinstein JA, et al: Surgical and interventional therapies for pulmonary arterial hypertension. *Semin Respir Crit Care Med* 2005; 26:417–428
48. Miro AM, Pinsky MR: Heart-lung interactions. In: Tobin MJ (Ed). *Principles and Practice of Mechanical Ventilation*. New York, NY, McGraw-Hill, 1994, pp 647–672
49. Artucio H, Hurtado J, Zimet L, et al: PEEP-induced tricuspid regurgitation. *Intensive Care Med* 1997; 23:836–840
50. Jardin F, Vieillard-Baron A: Right ventricular function and positive pressure ventilation in clinical practice: From hemodynamic subsets to respirator settings. *Intensive Care Med* 2003; 29:1426–1434
51. Carvalho CRR, Barbas CSV, Medeiros DM, et al: Temporal hemodynamic effects of permissive hypercapnia associated with ideal PEEP in ARDS. *Am J Respir Crit Care Med* 1997; 156:1458–1466
52. Viitanen A, Salmenpera M, Heinonen J: Right ventricular response to hypercarbia after cardiac surgery. *Anesthesiology* 1990; 73:393–400
53. Balanos GM, Talbot NP, Dorrington KL, et al: Human pulmonary vascular response to 4 h of hypercapnia and hypocapnia measured using Doppler echocardiography. *J Appl Physiol* 2003; 94:1543–1551
54. Leier CV, Weibel J, Bush CA: The cardiovascular effects of the continuous infusion of dobutamine in patients with severe cardiac failure. *Circulation* 1977; 56:468–472
55. Kerbaul F, Rondelet B, Motte S, et al: Effects of norepinephrine and dobutamine on pressure load-induced right ventricular failure. *Crit Care Med* 2004; 32:1035–1040
56. Bradford KK, Deb B, Pearl RG: Combination therapy with inhaled nitric oxide and intravenous dobutamine during pulmonary hypertension in the rabbit. *J Cardiovasc Pharmacol* 2000; 36:146–151
57. Steendijk P: Right ventricular function and failure: Methods, models, and mechanisms. *Crit Care Med* 2004; 32:1087–1089
58. Vizza CD, Rocca GD, Roma AD, et al: Acute hemodynamic effects of inhaled nitric oxide, dobutamine, and a combination of the two in patients with mild to moderate secondary pulmonary hypertension. *Crit Care* 2001; 5:355–361
59. Kwak YL, Lee CS, Park YH, et al: The effect of phenylephrine and norepinephrine in patients with chronic pulmonary hypertension*. *Anaesthesia* 2002; 57:9–14
60. Ducas J, Duval D, Dasilva H, et al: Treatment of canine pulmonary hypertension: Effects of norepinephrine and isoproterenol on pulmonary vascular pressure-flow characteristics. *Circulation* 1987; 75:235–242
61. Tritapepe L, Voci P, Cogliati AA, et al: Successful weaning from cardiopulmonary bypass with central venous prostaglandin E₁ and left atrial norepinephrine infusion in patients with acute pulmonary hypertension. *Crit Care Med* 1999; 27:2180–2183
62. Lollgen H, Drexler H: Use of inotropes in the critical care setting. *Crit Care Med* 1990; 18:S56–S60
63. Ducas J, Stitz M, Gu S, et al: Pulmonary vascular pressure-flow characteristics. Effects of dopamine before and after pulmonary embolism. *Am Rev Respir Dis* 1992; 146:307–312
64. Holloway EL, Polumbo RA, Harrison DC: Acute circulatory effects of dopamine in patients with pulmonary hypertension. *Br Heart J* 1975; 37:482–485
65. Rich S, Gubin S, Hart K: The effects of phenylephrine on right ventricular performance in patients with pulmonary hypertension. *Chest* 1990; 98:1102–1106
66. Tisdale JE, Patel RV, Webb CR, et al: Proarrhythmic effects of intravenous vasopressors. *Ann Pharmacother* 1995; 29:269–281
67. Prielipp RC, McLean R, Rosenthal MH, et al: Hemodynamic profiles of prostaglandin E₁, isoproterenol, prostacyclin, and nifedipine in experimental porcine pulmonary hypertension. *Crit Care Med* 1991; 19:60–67
68. Garcia-Villalon AL, Garcia JL, Fernandez N, et al: Regional differences in the arterial response to vasopressin: Role of endothelial nitric oxide. *Br J Pharmacol* 1996; 118: 1848–1854
69. Evora PR, Pearson PJ, Schaff HV: Arginine vasopressin induces endothelium-dependent vasodilatation of the pulmonary artery. V1-receptor-mediated production of nitric oxide. *Chest* 1993; 103:1241–1245
70. Sai Y, Okamura T, Amakata Y, et al: Comparison of responses of canine pulmonary artery and vein to angiotensin II, bradykinin, and vasopressin. *Eur J Pharmacol* 1995; 282:235–241
71. Leather HA, Segers P, Berends N, et al: Effects of vasopressin on right ventricular function in an experimental model of acute pulmonary hypertension. *Crit Care Med* 2002; 30:2548–2552
72. Tsuneyoshi I, Yamada H, Kakihana Y, et al: Hemodynamic and metabolic effects of low-dose vasopressin infusions in vasodilatory septic shock. *Crit Care Med* 2001; 29: 487–493
73. Rossaint R, Gerlach H, Schmidt-Ruhnke H, et al: Efficacy of inhaled nitric oxide in patients with severe ARDS. *Chest* 1995; 107: 1107–1115
74. Pepke-Zaba J, Higenbottam TW, Dinh-Xuan AT, et al: Inhaled nitric oxide as a cause of selective pulmonary vasodilatation in pulmonary hypertension. *Lancet* 1991; 338: 1173–1174
75. Semigran MJ, Cockrill BA, Kacmarek R, et al: Hemodynamic effects of inhaled nitric oxide in heart failure. *J Am Coll Cardiol* 1994; 24:982–988
76. Girard C, Lehot JJ, Pannetier JC, et al: Inhaled nitric oxide after mitral valve replacement in patients with chronic pulmonary artery hypertension. *Anesthesiology* 1992; 77:880–883
77. Hart CM: Nitric oxide in adult lung disease. *Chest* 1999; 115:1407–1417
78. Kaisers U, Busch T, Deja M, et al: Selective pulmonary vasodilation in acute respiratory distress syndrome. *Crit Care Med* 2003; 31: S337–S342
79. Taylor RW, Zimmerman JL, Dellinger RP, et al: Low-dose inhaled nitric oxide in patients with acute lung injury: A randomized controlled trial. *JAMA* 2004; 291:1603–1609
80. Cockrill BA, Kacmarek RM, Fifer MA, et al: Comparison of the effects of nitric oxide, nitroprusside, and nifedipine on hemodynamics and right ventricular contractility in patients with chronic pulmonary hypertension. *Chest* 2001; 119:128–136
81. Bhorade S, Christenson J, O'Connor M, et al: Response to inhaled nitric oxide in patients with acute right heart syndrome. *Am J Respir Crit Care Med* 1999; 159: 571–579
82. Weinberger B, Laskin DL, Heck DE, et al: The toxicology of inhaled nitric oxide. *Toxicol Sci* 2001; 59:5–16
83. Wang T, El Kebir D, Blaise G: Inhaled nitric oxide in 2003: A review of its mechanisms of action. *Can J Anaesth* 2003; 50:839–846
84. Christenson J, Lavoie A, O'Connor M, et al: The incidence and pathogenesis of cardiopulmonary deterioration after abrupt withdrawal of inhaled nitric oxide. *Am J Respir Crit Care Med* 2000; 161:1443–1449
85. McLaughlin VV, Genthner DE, Panella MM, et al: Reduction in pulmonary vascular resistance with long-term epoprostenol (prostacyclin) therapy in primary pulmonary hypertension. *N Engl J Med* 1998; 338: 273–277
86. McLaughlin VV, Shillington A, Rich S: Survival in primary pulmonary hypertension: The impact of epoprostenol therapy. *Circulation* 2002; 106:1477–1482
87. Badesch DB, Tapson VF, McGoon MD, et al: Continuous intravenous epoprostenol for pulmonary hypertension due to the scleroderma spectrum of disease. A randomized, controlled trial. *Ann Intern Med* 2000; 132: 425–434

88. Barst RJ, Rubin LJ, Long WA, et al: A comparison of continuous intravenous epoprostenol (prostacyclin) with conventional therapy for primary pulmonary hypertension. *N Engl J Med* 1996; 334:296–302
89. Hache M, Denault AY, Belisle S, et al: Inhaled prostacyclin (PGI₂) is an effective addition to the treatment of pulmonary hypertension and hypoxia in the operating room and intensive care unit. *Can J Anaesth* 2001; 48:924–929
90. De Wet CJ, Affleck DG, Jacobsohn E, et al: Inhaled prostacyclin is safe, effective, and affordable in patients with pulmonary hypertension, right heart dysfunction, and refractory hypoxemia after cardiothoracic surgery. *J Thorac Cardiovasc Surg* 2004; 127:1058–1067
91. Gessler T, Schmehl T, Hoepfer MM, et al: Ultrasonic versus jet nebulization of iloprost in severe pulmonary hypertension. *Eur Respir J* 2001; 17:14–19
92. Hoepfer MM, Schwarze M, Ehlerding S, et al: Long-term treatment of primary pulmonary hypertension with aerosolized iloprost, a prostacyclin analogue. *N Engl J Med* 2000; 342:1866–1870
93. Hoepfer MM, Olschewski H, Ghofrani HA, et al: A comparison of the acute hemodynamic effects of inhaled nitric oxide and aerosolized iloprost in primary pulmonary hypertension. *J Am Coll Cardiol* 2000; 35: 176–182
94. Deb B, Bradford K, Pearl RG: Additive effects of inhaled nitric oxide and intravenous milrinone in experimental pulmonary hypertension. *Crit Care Med* 2000; 28: 795–799
95. Chen EP, Bittner HB, Davis RD Jr, et al: Milrinone improves pulmonary hemodynamics and right ventricular function in chronic pulmonary hypertension. *Ann Thorac Surg* 1997; 63:814–821
96. Khazin V, Kaufman Y, Zabeeda D, et al: Milrinone and nitric oxide: Combined effect on pulmonary artery pressures after cardiopulmonary bypass in children. *J Cardiothorac Vasc Anesth* 2004; 18:156–159
97. Matot I, Gozal Y: Pulmonary responses to selective phosphodiesterase-5 and phosphodiesterase-3 inhibitors. *Chest* 2004; 125: 644–651
98. Lepore JJ, Maroo A, Pereira NL, et al: Effect of sildenafil on the acute pulmonary vasodilator response to inhaled nitric oxide in adults with primary pulmonary hypertension. *Am J Cardiol* 2002; 90:677–680
99. Bhatia S, Frantz RP, Severson CJ, et al: Immediate and long-term hemodynamic and clinical effects of sildenafil in patients with pulmonary arterial hypertension receiving vasodilator therapy. *Mayo Clin Proc* 2003; 78:1207–1213
100. Michelakis E, Tymchak W, Lien D, et al: Oral sildenafil is an effective and specific pulmonary vasodilator in patients with pulmonary arterial hypertension: Comparison with inhaled nitric oxide. *Circulation* 2002; 105:2398–2403
101. Trachte AL, Lobato EB, Urdaneta F, et al: Oral sildenafil reduces pulmonary hypertension after cardiac surgery. *Ann Thorac Surg* 2005; 79:194–197
102. Krowka MJ, Mandell MS, Ramsay MA, et al: Hepatopulmonary syndrome and portopulmonary hypertension: A report of the multicenter liver transplant data base. *Liver Transplantation* 2004; 10:174–182
103. Rafanan AL, Maurer J, Mehta AC, et al: Progressive portopulmonary hypertension after liver transplantation treated with epoprostenol. *Chest* 2000; 188:1497–1500
104. Mikhail GW, Prasad SK, Li W, et al: Clinical and haemodynamic effects of sildenafil in pulmonary hypertension: Acute and mid-term effects. *Eur Heart J* 2004; 25:431–436
105. Lepore JJ, Maroo A, Bigatello LM, et al: Hemodynamic effects of sildenafil in patients with congestive heart failure and pulmonary hypertension: Combined administration with inhaled nitric oxide. *Chest* 2005; 127:1647–1653
106. Preston IR, Klinger JR, Houtches J, et al: Acute and chronic effects of sildenafil in patients with pulmonary arterial hypertension. *Respir Med* 2005; 99:1501–1510
107. Thusu KG, Morin FC, Russell JA, et al: The cGMP phosphodiesterase inhibitor zaprinast enhances the effect of nitric oxide. *Am J Respir Crit Care Med* 1995; 152: 1605–1610
108. Nagamine J, Hill LL, Pearl RG: Combined therapy with zaprinast and inhaled nitric oxide abolishes hypoxic pulmonary hypertension. *Crit Care Med* 2000; 28:2420–2424
109. Ghofrani HA, Wiedemann R, Rose F, et al: Combination therapy with oral sildenafil and inhaled iloprost for severe pulmonary hypertension. *Ann Intern Med* 2002; 136: 515–522
110. Ng J, Finney SJ, Shulman R, et al: Treatment of pulmonary hypertension in the general adult intensive care unit: A role for oral sildenafil? *Br J Anaesth* 2005; 94: 774–777
111. Atz AM, Wessel DL: Sildenafil ameliorates effects of inhaled nitric oxide withdrawal. *Anesthesiology* 1999; 91:307–310
112. Fung E, Fiscus RR, Yim A, et al: The potential use of type-5 phosphodiesterase inhibitors in coronary artery bypass graft surgery. *Chest* 2005; 128:3065–3073
113. O'dell KM, Kalus JS, Kucukarslan S, et al: Nesiritide for secondary pulmonary hypertension in patients with end-stage heart failure. *Am J Health-Syst Pharm* 2005; 62: 606–609
114. Yancy CW: Treatment with B-type natriuretic peptide for chronic decompensated heart failure: Insights learned from the follow-up serial infusion of nesiritide (FUSION) trial. *Heart Fail Rev* 2004; 9:209–216
115. Roberts DH, Lepore JJ, Maroo A, et al: Oxygen therapy improves cardiac index and pulmonary vascular resistance in patients with pulmonary hypertension. *Chest* 2001; 120:1547–1555
116. Moloney ED, Evans TW: Pathophysiology and pharmacological treatment of pulmonary hypertension in acute respiratory distress syndrome. *Eur Respir J* 2003; 21: 720–727
117. Magid JH, Manohar M, Goetz TE, et al: Pulmonary vascular pressures of thoroughbred horses exercised 1, 2, 3, and 4 h after furosemide administration. *J Vet Pharmacol Ther* 2000; 23:81–89
118. Rich S, Seidlitz M, Dodin E, et al: The short-term effects of digoxin in patients with right ventricular dysfunction from pulmonary hypertension. *Chest* 1998; 114: 787–792
119. Buller HR, Agnelli G, Hull RD, et al: Antithrombotic therapy for venous thromboembolic disease: The Seventh ACCP Conference on Antithrombotic and Thrombolytic Therapy. *Chest* 2004; 126:401S–428S
120. Dhainaut JF, Laterre PF, LaRosa SP, et al: The clinical evaluation committee in a large multicenter phase 3 trial of drotrecogin alfa (activated) in patients with severe sepsis (PROWESS): Role, methodology, and results. *Crit Care Med* 2003; 31:2291–2301
121. Laterre PF, Wittebole X, Dhainaut JF: Anticoagulant therapy in acute lung injury. *Crit Care Med* 2003; 31:S329–S336
122. Glanville AR, Burke CM, Theodore J, et al: Primary pulmonary hypertension. Length of survival in patients referred for heart-lung transplantation. *Chest* 1987; 91: 675–681
123. Young D, Mark H: Fate of the patient with the Eisenmenger syndrome. *Am J Cardiol* 1971; 28:658–669
124. Hopkins WE, Ochoa LL, Richardson GW, et al: Comparison of the hemodynamics and survival of adults with severe primary pulmonary hypertension or Eisenmenger syndrome. *J Heart Lung Transplant* 1996; 15: 105
125. Reichenberger F, Pepke-Zaba J, McNeil K, et al: Atrial septostomy in the treatment of severe pulmonary arterial hypertension. *Thorax* 2003; 58:797–800
126. Sandoval J, Gaspar J, Pulido T, et al: Graded balloon dilation atrial septostomy in severe primary pulmonary hypertension. A therapeutic alternative for patients nonresponsive to vasodilator treatment. *J Am Coll Cardiol* 1998; 32:297–304
127. Rothman A, Sklansky MS, Lucas VW, et al: Atrial septostomy as a bridge to lung transplantation in patients with severe pulmonary hypertension. *Am J Cardiol* 1999; 84: 682–686
128. Kasper W, Konstantinides S, Geibel A, et al: Management strategies and determinants of outcome in acute major pulmonary embolism: Results of a multicenter registry. *J Am Coll Cardiol* 1997; 30:1165–1171
129. Zeni PT, Blank BG, Peeler DW: Use of rheolytic thrombectomy in treatment of acute

- massive pulmonary embolism. *J Vasc Interv Radiol* 2003; 14:1511–1515
130. Yoshida M, Inoue I, Kawagoe T, et al: Novel percutaneous catheter thrombectomy in acute massive pulmonary embolism: Rotational bidirectional thrombectomy (ROBOT). *Catheter Cardiovasc Interv* 2006; 68: 112–117
 131. Perlroth DJ, Sanders GD, Gould MK: Effectiveness and cost-effectiveness of thrombolysis in submassive pulmonary embolism. *Arch Intern Med* 2007; 167:74–80
 132. Hirsch LJ, Rooney MW, Wat SS, et al: Norepinephrine and phenylephrine effects on right ventricular function in experimental canine pulmonary embolism. *Chest* 1999; 100:796–801
 133. Molloy WD, Lee KY, Girling L, et al: Treatment of shock in a canine model of pulmonary embolism. *Am Rev Respir Dis* 1984; 130:870–874
 134. Szold O, Khoury W, Biderman P, et al: Inhaled nitric oxide improves pulmonary functions following massive pulmonary embolism: A report of four patients and review of literature. *Lung* 2006; 184:1–5
 135. Mahoney PD, Loh E, Blitz LR, et al: Hemodynamic effects of inhaled nitric oxide in women with mitral stenosis and pulmonary hypertension. *Am J Cardiol* 2001; 87: 188–192
 136. Kuo PC, Plotkin JS, Johnson LB, et al: Distinctive clinical features of portopulmonary hypertension. *Chest* 1997; 112:980–986
 137. Kuo PC, Johnson LB, Plotkin JS, et al: Continuous intravenous infusion of epoprostenol for the treatment of portopulmonary hypertension. *Transplantation* 1997; 63: 604–606
 138. Sussman N, Kaza V, Barshes N, et al: Successful liver transplantation following medical management of portopulmonary hypertension: A single-center series. *Am J Transplant* 2006; 6:2177–2182
 139. Tan HP, Markowitz JS, Montgomery RA, et al: Liver transplantation in patients with severe portopulmonary hypertension treated with preoperative chronic intravenous epoprostenol. *Liver Transpl* 2001; 7:745–749
 140. Reichenberger F, Voswinckel R, Steveling E, et al: Sildenafil treatment for portopulmonary hypertension. *Eur Respir J* 2006; 28:563–567
 141. Chua R, Keogh A, Miyashita M: Novel use of sildenafil in the treatment of portopulmonary hypertension. *J Heart Lung Transplant* 2005; 24:498–500
 142. Saner FH, Nadalin S, Pavlakovic G, et al: Portopulmonary hypertension in the early phase following liver transplantation. *Transplantation* 2006; 82:887–891
 143. Ramsay MA: The perioperative management of portopulmonary hypertension with NO and epoprostenol. *Anesthesiology* 1999; 90: 299–301
 144. Bernstein AD, Parsonnet V: Bedside estimation of risk as an aid for decision-making in cardiac surgery. *Ann Thorac Surg* 2000; 69: 823–828
 145. Ng CS, Wan S, Yim AP, et al: Pulmonary dysfunction after cardiac surgery. *Chest* 2002; 121:1269–1277
 146. Lamarche Y, Malo O, Thorin E, et al: Inhaled but not intravenous milrinone prevents pulmonary endothelial dysfunction after cardiopulmonary bypass. *J Thorac Cardiovasc Surg* 2005; 130:83–92
 147. Fattouch K, Sbraga F, Sampognaro R, et al: Treatment of pulmonary hypertension in patients undergoing cardiac surgery with cardiopulmonary bypass: A randomized, prospective, double-blind study. *J Cardiovasc Med (Hagerstown)* 2006; 7:119–123
 148. Della Rocca G, Coccia C: Nitric oxide in thoracic surgery. *Minerva Anestesiol* 2005; 71:313–318
 149. Fattouch K, Sbraga F, Bianco G, et al: Inhaled prostacyclin, nitric oxide, and nitroprusside in pulmonary hypertension after mitral valve replacement. *J Card Surg* 2005; 20:171–176
 150. Lawson SM, Doctor A, Walsh BK, et al: Inhaled prostacyclin for the treatment of pulmonary hypertension after cardiac surgery. *Crit Care Med* 2002; 30:2762–2764
 151. Stobierska-Dzierzek B, Awad H, Michler RE: The evolving management of acute right-sided heart failure in cardiac transplant recipients. *J Am Coll Cardiol* 2001; 38:923–931
 152. George I: Clinical indications for use and outcomes after iNO therapy. *Ann Thorac Surg* 2006; 82:2161–2169
 153. Ardehali A, Hughes K, Sadeghi A, et al: Inhaled nitric oxide for pulmonary hypertension after heart transplantation. *Transplantation* 2001; 72:638–641
 154. Solina A, Papp D, Ginsberg S, et al: A comparison of inhaled nitric oxide and milrinone for the treatment of pulmonary hypertension in adult cardiac surgery patients. *J Cardiothorac Vasc Anesth* 2000; 14:12–17
 155. Theodoraki K, Rellia P, Thanopoulos A, et al: Inhaled iloprost controls pulmonary hypertension after cardiopulmonary bypass. *Can J Anesth* 2002; 49:963–967
 156. Theodoraki K, Tsiapras D, Tsourelis L, et al: Inhaled iloprost in eight heart transplant recipients presenting with post-bypass acute right ventricular dysfunction. *Acta Anaesthesiol Scand* 2006; 50:1213–1217
 157. Atz AM, Lefler AK, Fairbrother DL, et al: Sildenafil augments the effect of inhaled nitric oxide for postoperative pulmonary hypertension crisis. *J Thorac Cardiovasc Surg* 2002; 124:628–629
 158. Klodell CT, Morey TE, Lobato EB, et al: Effect of sildenafil on pulmonary artery pressure, systemic pressure, and nitric oxide utilization in patients with left ventricular assist devices. *Ann Thorac Surg* 2007; 83:68–71
 159. Al-Khaldi A, Reitz B, Zhu H, et al: Heterotopic heart transplant combined with postoperative sildenafil use for the treatment of restrictive cardiomyopathy. *Ann Thorac Surg* 2006; 81:1505–1507
 160. Mandel J, Mark EJ, Hales CA: Pulmonary veno-occlusive disease. *Am J Respir Crit Care Med* 2000; 162:1964–1973
 161. Resten A, Maitre S, Humbert M, et al: Pulmonary hypertension: CT of the chest in pulmonary venoocclusive disease. *AJR Am J Roentgenol* 2004; 183:65–70
 162. Budev M, Arroliga A, Emery S: Exacerbation of underlying pulmonary disease in pregnancy. *Crit Care Med* 2005; 33:S313–S318
 163. Segal ES, Valette S, Oster L, et al: Risk management strategies in postmarketing period; safety experience with the US and European bosentan surveillance programmes. *Drug Saf* 2005; 28:971–980