

Cardiac Sarcoidosis: A Resonating Diagnosis

Shea Clafin, MS2¹ and Elizabeth Gillespie, MD²

¹University of Colorado School of Medicine, Denver, CO.

²Department of Medicine-Hospital Medicine, University of Colorado, Denver, CO.

Introduction

Sarcoidosis is a granulomatous disease of unknown etiology that has various clinical presentations dependent upon its systemic involvement.¹ Approximately 5% of patients diagnosed with sarcoidosis also meet clinical criteria for cardiac sarcoidosis (CS), whereas subclinical cardiac involvement is observed in 20-50% of cases.^{2,3}

Common clinical presentations include:²

- Syncope, palpitations, chest pain
- AV block – Mobitz I and II, 3rd degree AV block
- Ventricular tachycardia and fibrillation
- Sudden cardiac death
- Less common: heart failure, valvular abnormalities⁴

Though the true prevalence of CS is unknown, there is evidence that is associated with a poorer prognosis.⁵

Case Description

History:

Mr. D is a 46 yo male who presents for evaluation of palpitations, syncopal episodes, and shortness of breath on exertion. During transfer to Denver Health for chest pain and abnormal EKG findings of 1st degree AV block and SVT, he experienced a pre-syncopal episode preceded by light-headedness and dizziness. Providers at the transferring facility had recently observed 2nd degree Mobitz I AV block (while on a beta blocker). Mr. D reports 5 years of intermittent chest pain and syncope. He has taken metoprolol for the past 14 years, for nonspecific tachyarrhythmia and palpitations.

Studies:

- EKG: 2nd degree AV block Mobitz II, prolonged QTc, PVCs
- Telemetry: Mobitz I and II, 3rd degree AV block
- CXR: perihilar prominence, streaky opacities
- Echocardiogram: thinner basal antero-septum
- CMR: late gadolinium enhancement
- Chest CT: scattered bilateral pulmonary nodules
- Transbronchial biopsy – no granulomas identified

Management:

- Dual chamber pacemaker with ICD
- Ophthalmology exam normal
- Discharged on metoprolol for continued palpitations and escitalopram for anxiety surrounding newly diagnosed heart condition

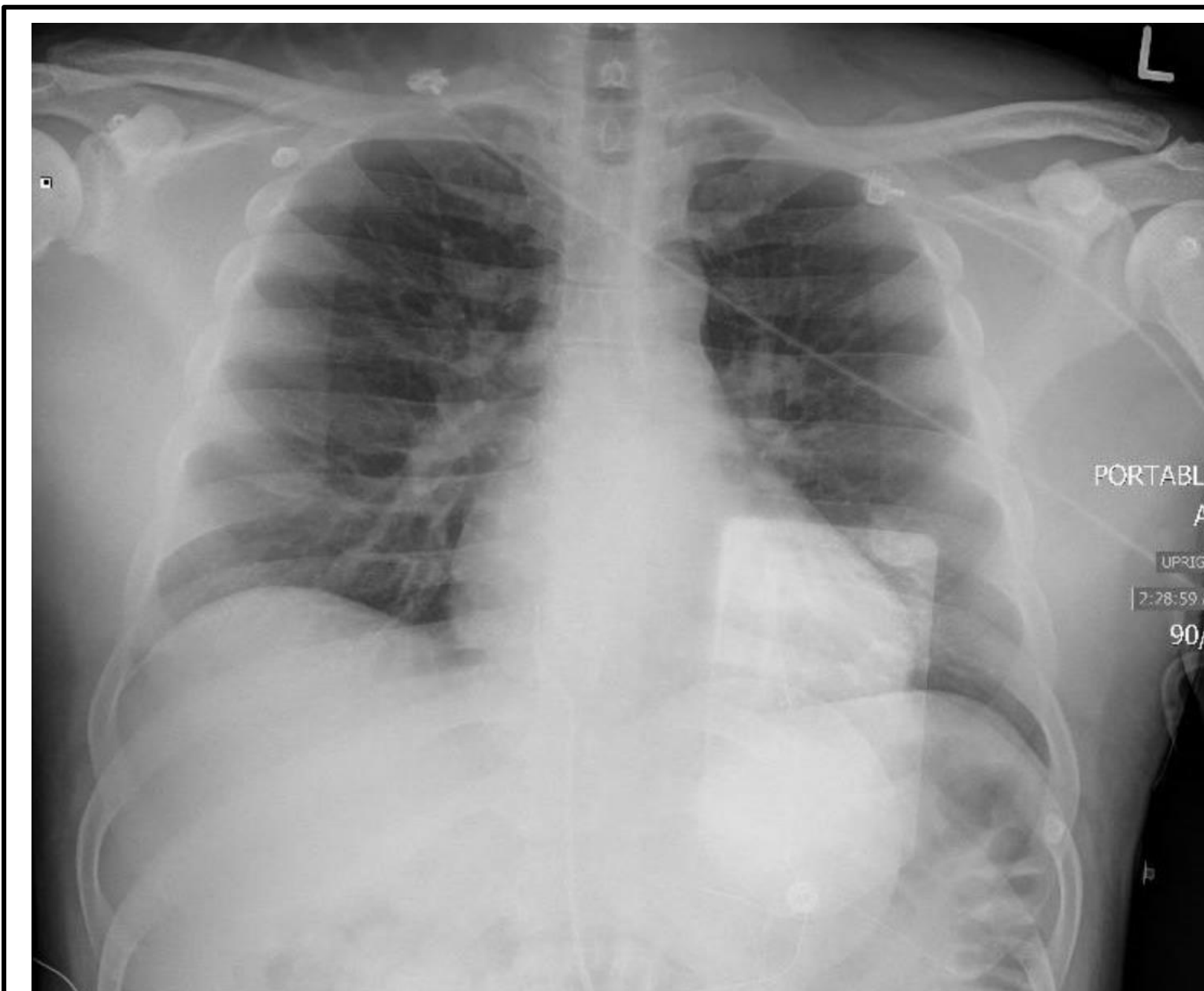
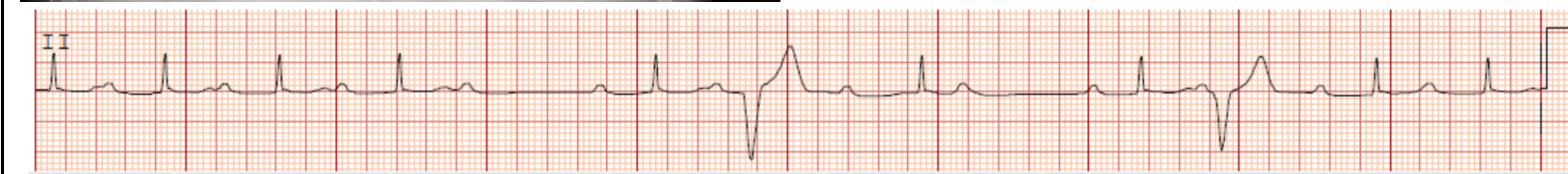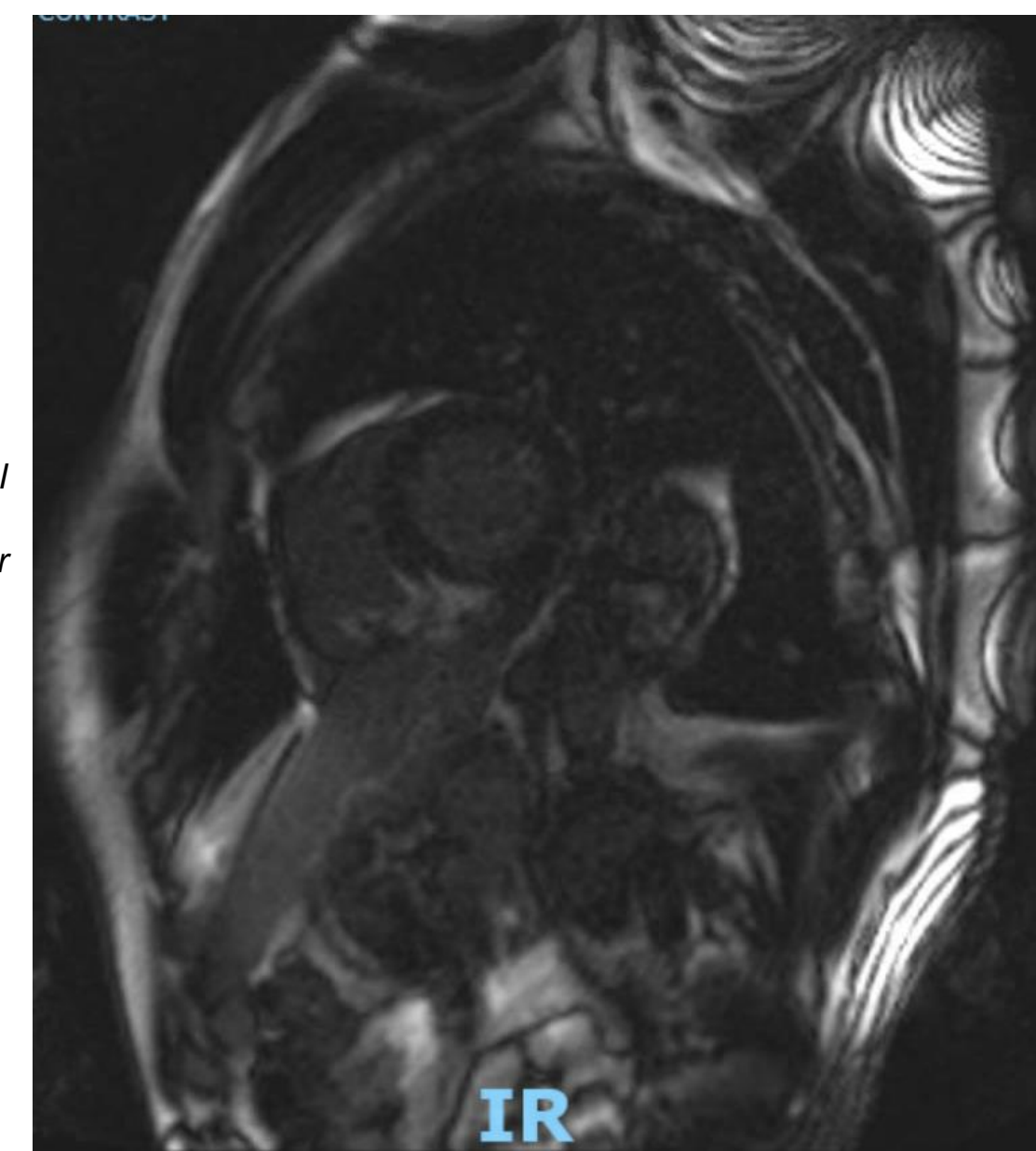


Figure 1. (left)
Initial Chest X-Ray demonstrated perihilar prominence and streaky retrocardiac opacities.

Figure 2. (right)
Cardiac MRI demonstrated late gadolinium enhancement with epicardial predominance, involving basilar anterior and posterior insertion of RV walls into IV septum, and inferior insertion extending to midventricle and involving inferior RV free wall.

Figure 3. (below)
ED EKG revealed Mobitz II, prolonged qTc interval, and PVC.



Discussion

Cardiac sarcoidosis often presents with nonspecific symptoms and findings on studies like EKG and echocardiogram. The gold standard for diagnosis is endomyocardial biopsy, but this has a low sensitivity of 20-30% in exchange for a high risk of complications. Thus, the diagnosis can be challenging to make, so a high index of clinical suspicion is of utmost importance. Suspect CS in patients with new onset conduction abnormalities, unexplained syncope, unexplained cardiomyopathy, unexplained sudden cardiac death, and sustained ventricular tachycardia.^{2,6}

There are currently three sets of clinical criteria that can be used to make the diagnosis of CS: the Japanese Ministry of Health and Welfare (JMHWF), the Heart Rhythm Society (HRS), and the World Association for Sarcoidosis and Other Granulomatous Disorders.⁷ A generalized diagnostic approach that most closely resembles the HRS guidelines is shown below:⁸

H&P w/ 12-lead ECG (and echocardiogram)

Evaluation for patients with previously confirmed extracardiac sarcoidosis or those under clinical suspicion for CS.

CMR or FDG-PET

Advanced Cardiac Imaging Criteria:
With extracardiac sarcoidosis

- Palpitations, presyncope, syncope
- ECG abnormalities
- Echo abnormalities

Without extracardiac sarcoidosis:

- Unexplained Mobitz II or 3rd degree block, age <60
- Sustained monomorphic ventricular tachycardia

Histologic Confirmation

Biopsy is required for definitive diagnosis, whether endomyocardial biopsy or extracardiac.

CS management consists of immunosuppressive therapies, medical or surgical management of conduction abnormalities, and goal-directed therapy for heart failure.

References

1. Llanos O, Hamzeh N. Sarcoidosis. Med Clin North Am. 2019 May;103(3):527-534. doi: 10.1016/j.mcna.2018.12.011. Epub 2019 Feb 21. PMID: 30955519.
2. Kusano KF, Satomi K. Diagnosis and treatment of cardiac sarcoidosis. Heart. 2016 Feb;102(3):184-90. doi: 10.1136/heartjnl-2015-307877. Epub 2015 Dec 7. PMID: 26643814.
3. Youssef G, Leung E, Mylonas I, Nery P, Williams K, Wisenberg G, Gulenchyn KY, Dekemp RA, Dasilva J, Birnie D, Wells GA, Beanlands RS. The use of 18F-FDG PET in the diagnosis of cardiac sarcoidosis: a systematic review and metaanalysis including the Ontario experience. J Nucl Med. 2012 Feb;53(2):241-8. doi: 10.2967/jnumed.111.090662. Epub 2012 Jan 6. PMID: 22228794.
4. Yatsynovich Y, Dittoe N, Petrov M, Maroz N. Cardiac Sarcoidosis: A Review of Contemporary Challenges in Diagnosis and Treatment. Am J Med Sci. 2018 Feb;355(2):113-125. doi: 10.1016/j.amjms.2017.08.009. Epub 2017 Aug 18. PMID: 29406038.
5. Mcbeath K, Honarbakhsh S, Chowdhury M, Farooqi F. Undiagnosed cardiac sarcoidosis presenting as complete heart block and ventricular arrhythmia. BMJ Case Rep. 2015;2015:bcr2015211736. Published 2015 Aug 17. doi:10.1136/bcr-2015-211736
6. Kawai H, Sarai M, Kato Y, Naruse H, Watanabe A, Matsuyama T, Takahashi H, Motoyama S, Ishii J, Morimoto SI, Toyama H, Ozaki Y. Diagnosis of isolated cardiac sarcoidosis based on new guidelines. ESC Heart Fail. 2020 Oct;7(5):2662-2671. doi: 10.1002/ehf2.12853. Epub 2020 Jun 24. PMID: 32578957; PMCID: PMC7524076.
7. Ribeiro Neto ML, Jellis CL, Joyce E, Callahan TD, Hachamovitch R, Culver DA. Update in Cardiac Sarcoidosis. Ann Am Thorac Soc. 2019 Nov;16(11):1341-1350. doi: 10.1513/AnnalsATS.201902-119CME. PMID: 31322914.
8. Birnie DH, Sauer WH, Bogun F, Cooper JM, Culver DA, Duvernoy CS, Judson MA, Kron J, Mehta D, Cosedis Nielsen J, Patel AR, Ohe T, Raatikainen P, Soejima K. HRS expert consensus statement on the diagnosis and management of arrhythmias associated with cardiac sarcoidosis. Heart Rhythm. 2014 Jul;11(7):1305-23. doi: 10.1016/j.hrthm.2014.03.043. Epub 2014 May PMID: 24819193.

Disclosures

We have no disclosures.