

Introduction

- Large variability in pancreatic venous anatomy [1,2].
- Purpose: create map of pancreatic veins and variations using three phase liver CT scans.
- We aim to use this information to conduct future studies involving venous sampling procedures and immunotherapy catheter directed approaches for pancreatic cancer
- We want to conduct trials for Pancreatic Retrograde Venous Infusion (PRVI™) Pressure Enabled Drug Delivery (PEDD™) trials for locally advanced pancreatic ductal adenocarcinoma (PDAC)
- PDAC is most common pancreatic cancer (80% of all pancreatic cancer cases).
- 5-year relative survival rate of PDAC is 7.2% [3]
- The PRVI™ PEDD™ system could provide more direct venous access to PDAC [4].

Methods

CT Background

- 117 three phase liver CT scans from November 2020 to October 2021
- Obtained from PACS (Primordial) system and electronic medical record (EPIC)
- CT Scans were from patients ages ≥18 yo at University of Colorado Hospital (UCH)

Data Analysis Software:

- REDCap was utilized for data recording and analysis

Recorded Variables:

- Number of pancreatic veins
- Best phase visualized: arterial, venous, portal
- Specific draining vein: superior mesenteric, portal, central splenic vein (Figure 1)
- Part of pancreas that vein drains: head, body, tail (Figure 1)
- Length of vein (for parameters of PEDD catheter placement)
- Veins greater than 10 or 20 mm
- Diameter of vein at origin and at 20 cm (for parameters of PEDD catheter placement)
- Angle of insertion into draining vein (for parameters of PEDD catheter placement) (Figure 2)
- Tortuosity of vein: none, mild, moderate, severe (Figure 3)
- Vein visualization in pancreas
- Presence of intra-parenchymal collateralization (Figure 4)
- Presence of pancreatic cancer

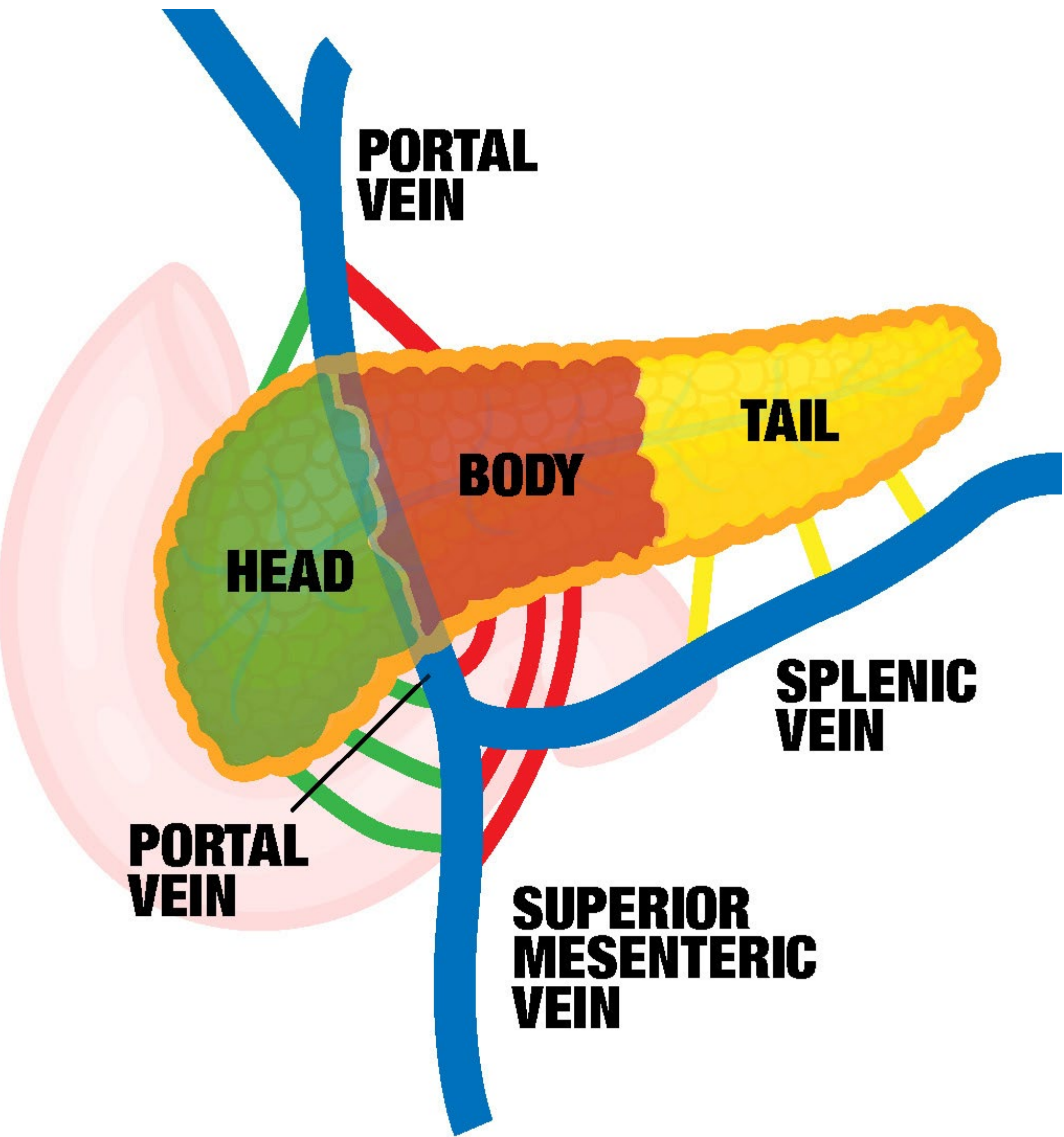


Figure 1. Drawing of pancreas anatomy detailing its parts and specific draining veins. Highlighted in green is the head of the pancreas, in red the body and in purple the tail. The major draining veins, portal, superior mesenteric vein, and splenic veins are drawn in blue. Tributaries connected to the head, body, and tail are shown in green, red, and yellow respectively.

Methods

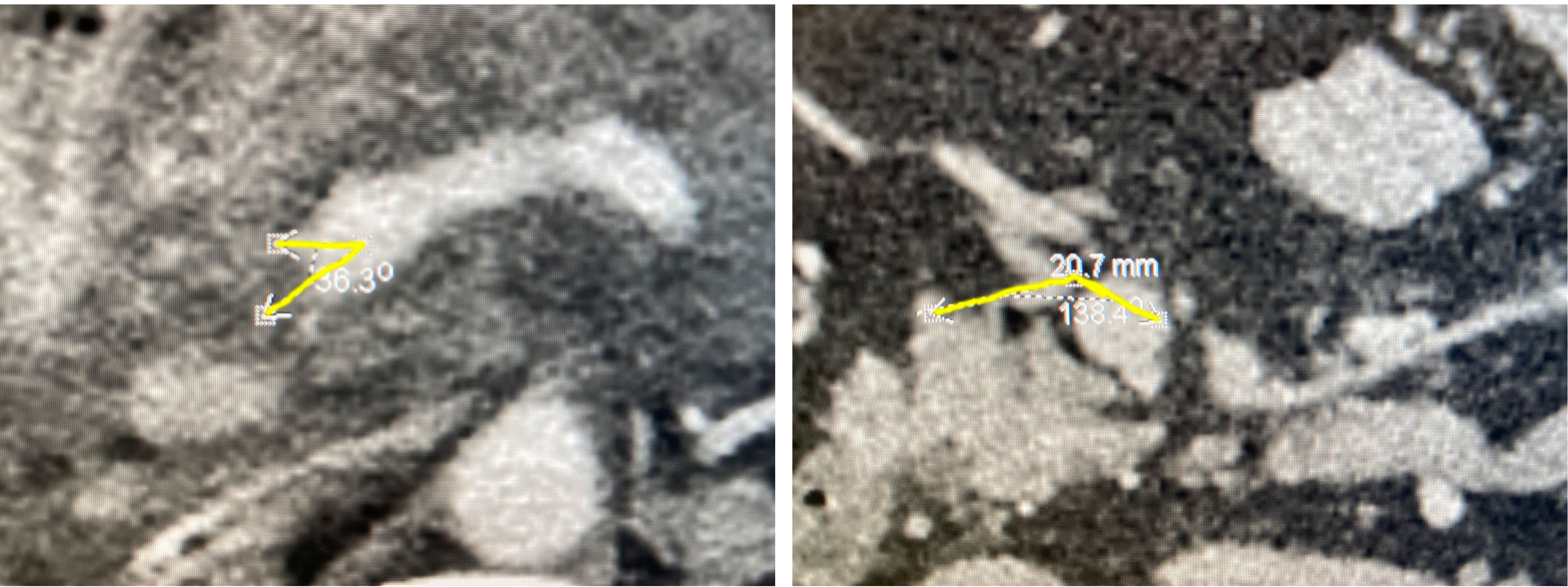


Figure 2. Angle of Insertion: Left image shows a portal vein draining the pancreatic head at an angle of insertion of 36.3° and right image shows a superior mesenteric vein draining the pancreatic head at an angle of 138.4°. The broader angle is more ideal for catheter placement.

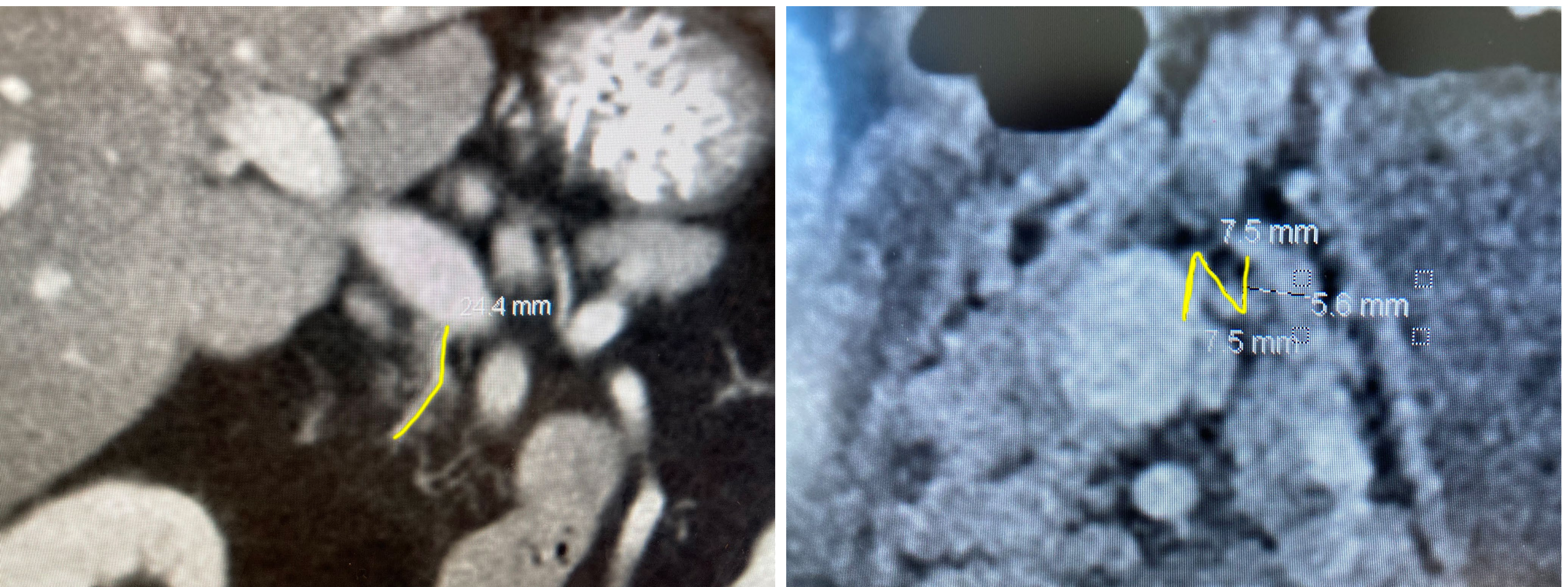


Figure 3. Tortuosity. Left image shows a portal vein draining the pancreatic head with a mild tortuosity and right image shows a portal vein draining the pancreatic body with a severe tortuosity. Less tortuosity is more ideal for catheter placement.

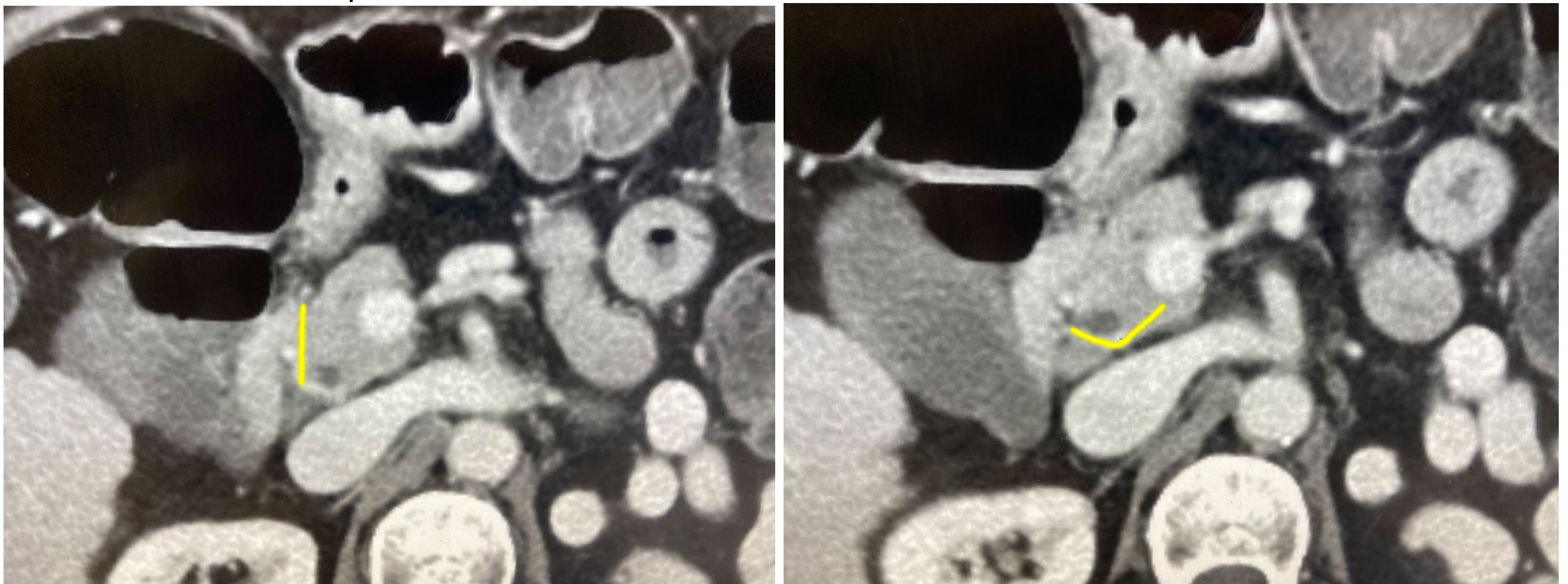


Figure 4. Intra-parenchymal collateralization. SMV vein collateralizing to anterior superior pancreaticoduodenal vein arcade around pancreatic head. The vein on the left highlighted in yellow continues its path in the image on the right around the pancreatic head.

Results

	Vessel Measurements (mm) ±SD				Tortuosity (%)			
	Origin diameter	Diameter at 2 cm	Length	Angle	None	Mild	Moderate	Severe
Head	3.22±1.13	3.20±1.19	22.39±15.25	86.73±36.86	30.2	37.2	27.3	5.3
Body	2.88±1.34	2.72±1.29	13.76±6.85	86.23±31.42	42	37.7	13	7.3
Tail	2.82±0.87	2.64±0.93	13.08±9.58	94.54±35.69	67.9	22	7.3	2.8

Veins longer than 20 mm

	Vessel Measurements						Vessel Tortuosity (%)			
	Diameter 20 mm from Origin	SD	Length	SD	Angle	SD	None	Mild	Moderate	Severe
Head	3.20	1.19	34.47	12.55	96.47	38.10	3.5%	44.7%	43.5%	8.3%
Body	2.72	1.29	23.44	4.80	88.91	28.99	0%	56.2%	18.8%	25.0%
Tail	2.64	0.93	29.52	11.65	92.69	38.91	27.8%	50.0%	22.2%	0%

- 350 veins over 117 CT scans
- Mean # of veins per patient: 2.99 ± 1.00
- 285 veins were best seen in the portal phase, 14 in the arterial, 41 in the venous, & 10 with a combination of arterial & portal phase
- 172 veins drained the pancreatic head, 69 the body, and 109 the tail
- Collateralization: 4 veins (head), 1 (body) and 1 (tail)
- 293 veins were between 2 & 6 mm in diameter at the origin (83.7%)

Conclusions

- Vein diameter are consistent with ability to canulate the veins from portal access based on CT findings.
- 83.7% of veins had adequate diameters & 59.4% were of at least 10mm length, should be sufficient for Pancreatic Retrograde Venous Infusion (PRVI™) Pressure Enabled Drug Delivery (PEDD™) trials



References

1. Mourad N, Zhang J, Rath AM, Chevrel JP. The venous drainage of the pancreas. Surg Radiol Anat. 1994;16(1):37-45. doi: 10.1007/BF01627919. PMID: 8047967.

2. Crabo LG, Conley DM, Graney DO, Freeny PC. Venous anatomy of the pancreatic head: normal CT appearance in cadavers and patients. AJR Am J Roentgenol. 1993 May;160(5):1039-45. doi: 10.2214/ajr.160.5.8385877. PMID: 8385877.

3. Ducreux M. Cancer of the Pancreas: ESMO Clinical Practice Guidelines for diagnosis, treatment and follow-up. Gastrointestinal Cancers. 2015; 26(5): 56-68.

4. Arepally A, Chomas J, Katz SC, et al. Pressure-Enabled Drug Delivery Approach in the Pancreas with Retrograde Venous Infusion of Lipiodol with Ex Vivo Analysis. Cardiovasc Intervent Radiol. 2021;44(1):141-149. doi:10.1007/s00270-020-02625-z

Disclosures

Mr. Kwong, Ms. Spears, and Dr. Pattee have no relevant disclosures. Dr. Steven Katz is the Chief Medical Officer of TriSalus and owns stock options with Trisalus. Dr. McLennan has stock options with Trisalsus. This project is funded by Trisalsus Life Sciences.