

tor (probably in the 7th century). The four original families² have a common link around the year 1720. Some clinical features are similar (age at onset, initial symptom, and unilateral foot dystonia). The course was more benign than in other patients with PD.

Together, the present observations and those listed in relation to *LRRK2* mutations imply that the presence of LBs and neurites, NFTs, ubiquitin-immunoreactive inclusions, and rare *LRRK2*-positive neurites are not essential findings in PD linked with *LRRK2* mutations.

Author Roles: J.-F.M.-M.: diagnosis and management of the patient, conception, organization, and execution of the research, writing of the first draft, review, and critique of the manuscript; J.R.-M.: conception and execution of the research project, writing of the first draft, review, and critique of the manuscript; M.J.B.: execution of the research project, review and critique of the manuscript; I.R.: pathology study; A.G.: molecular study, review and critique of the manuscript; F.M.: execution of the research project, review and critique of the manuscript; I.F.: execution of the research project, writing of the first draft, review, and critique of the manuscript, pathology study; A.L. de M.: conception and execution of the research project, writing of the first draft, review, and critique of the manuscript, coordination. J.-F.M.-M. and J.R.-M. contributed equally to this work.

REFERENCES

- Zimprich A, Biskup S, Leitner P, et al. Mutations in *LRRK2* cause autosomal-dominant parkinsonism with pleomorphic pathology. *Neuron* 2004;44:601–607.
- Paisán-Ruiz C, Jain S, Evans EW, et al. Cloning of the gene containing mutations that cause PARK8-linked Parkinson's disease. *Neuron* 2004;44:595–600.
- Simon-Sanchez J, Marti-Masso JF, Sanchez-Mut JV, et al. Parkinson's disease due to the R1441G mutation in Dardarin: a founder effect in the Basques. *Mov Disord* 2006;21:1954–1959.
- Gelb DJ, Oliver E, Gilman S. Diagnostic criteria for Parkinson disease. *Arch Neurol* 1999;56:33–39.
- Gilks WP, Abou-Sleiman PM, Gandhi S, et al. A common *LRRK2* mutation in idiopathic Parkinson's disease. *Lancet* 2005;365:415–416.
- Ross OA, Toft M, Whittle AJ, et al. *LRRK2* and Lewy body disease. *Ann Neurol* 2006;59:388–393.
- Giasson BI, Covy JP, Bonini NM, et al. Biochemical and pathological characterization of *LRRK2*. *Ann Neurol* 2006;59:315–322.
- Gaig C, Martí MJ, Ezquerro M, Rey MJ, Cardozo A, Tolosa E. G2019S *LRRK2* mutation causing Parkinson's disease without Lewy bodies. *J Neurol Neurosurg Psychiatry* 2007;78:626–628.
- Rajput A, Dickson DW, Robinson CA, et al. *LRRK2* G2019S, and tau neuropathology. *Neurology* 2006;67:1506–1508.
- Funayama M, Hasegawa K, Ohta E, et al. An *LRRK2* mutation as a cause for the parkinsonism in the original PARK8 family. *Ann Neurol* 2005;57:918–921.
- Hasegawa K, Kowa H. Autosomal dominant familial Parkinson disease: older onset of age, and good response to levodopa therapy. *Eur Neurol* 1997;38(Suppl 1):39–43.
- Khan NL, Jain S, Lynch JM, et al. Mutations in the gene *LRRK2* encoding dardarin (PARK8) cause familial Parkinson's disease: clinical, pathological, olfactory, and functional imaging and genetic data. *Brain* 2005;128:2786–2796.
- Giordana MT, D'Agostino C, Albani G, et al. Neuropathology of Parkinson's disease associated with the *LRRK2* Ile1371Val mutation. *Mov Disord* 2007;22:275–278.
- Mori H, Kondo T, Yokochi M, et al. Pathological and biochemical studies of juvenile parkinsonism linked to chromosome 6q. *Neurology* 1998;51:890–892.
- Khan NL, Graham E, Critchley P, et al. *Parkin* disease: a phenotypic study of a large case series. *Brain* 2003;126:1279–1292.

Tremor in 48,XXYY Syndrome

Nicole Tartaglia, MD,^{1*} Mariya Borodyanskya, BA,² and Deborah A. Hall, MD, PhD³

¹Department of Pediatrics, School of Medicine, University of Colorado Denver, Colorado, USA; ²Department of Pediatrics, M.I.N.D. Institute, University of California, Davis Medical Center, Sacramento, California, USA; ³Department of Neurology, School of Medicine, University of Colorado Denver, Colorado, USA

Video 

Abstract: The 48,XXYY syndrome is a form of sex chromosome aneuploidy presenting in 1:18,000 males. Tremor has been previously reported in 47,XXY and 47,XYY syndromes, but has not been well described in 48,XXYY syndrome. Ten males with 48,XXYY syndrome had a standardized neurological examination and videotaping, which included the Clinical Rating Scale for Tremor and the International Cooperative Ataxia Rating Scale. All 10 cases had postural and kinetic tremor on physical examination. Other findings included mild gait ataxia, dysarthria, and nystagmus. Three cases are reviewed. Tremor is a common finding in children and young adults with 48,XXYY syndrome. Dosage alteration of genes on the sex chromosomes may be involved in the pathogenesis of this tremor. Karyotyping should be considered in individuals presenting with tremor and a history of developmental delay, learning disabilities, tall stature, or microorchidism. © 2009 Movement Disorder Society

Key words: XXYY syndrome; sex chromosome abnormality; XYY; XXY; Klinefelter syndrome; tremor

Additional Supporting Information may be found in the online version of this article.

*Correspondence to: Asst. Prof. Nicole Tartaglia, Department of Pediatrics, University of Colorado Denver, School of Medicine, Child Development Unit, The Children's Hospital, 13123 East 16th Ave, B-140, Aurora, Colorado 80045. E-mail: tartaglia.nicole@tchden.org

Potential conflict of interest: The authors report no conflict of interest.

Received 9 September 2009; Revised 17 March 2009; Accepted 12 June 2009

Published online 24 August 2009 in Wiley InterScience (www.interscience.wiley.com). DOI: 10.1002/mds.22700

48,XXYY syndrome is a rare form of sex chromosome aneuploidy occurring in approximately 1:18,000 males. 48,XXYY syndrome was previously considered a variant of Klinefelter syndrome (47,XXY) due to a similar physical phenotype including tall stature, hypergonadotropic hypogonadism, and microorchidism. However, a distinct phenotype is now recognized to include additional medical problems and more significant cognitive and psychological impairments.^{1,2} Tremor has been previously described in case reports in 48,XXYY syndrome³⁻⁵ and "essential tremor" has also been reported in children and adults with other common forms of sex chromosome aneuploidy, including 47,XXY and 47,XYY syndromes.⁶⁻⁹ It has been hypothesized that dosage alteration of genes on the sex chromosomes may predispose to the development of tremor.¹⁰ In this article, we present the results of standardized neurological examinations in 10 males with 48,XXYY syndrome with tremor to document and further characterize this finding in 48,XXYY syndrome. We also describe three cases and include the first video series of tremor in 48,XXYY syndrome.

SUBJECTS AND METHODS

The 10 subjects in this case series were ascertained during an annual XXYY meeting in New York, in 2007, at which 28 males aged 3–26 years with 48,XXYY and their families were in attendance. All males with 48,XXYY at the meeting with minimal to severe tremor were invited to participate ($n = 14$); 4 subjects declined due to interest in other activities. The other 14 males with XXYY at the meeting (9 males age 2–13; 5 males age 14+) did not report tremor symptoms and were not evaluated due to time constraints. The 10 subjects signed Institutional Review Board (IRB)-approved consent forms and additional consent for videotaping. Seven of the 10 subjects had been previously evaluated and included in a larger study on medical and psychological features in XXYY syndrome,¹ the other three were not included in our previous research. Each subject had a standardized medical history, neurological examination, and was videotaped by a neurologist specializing in movement disorders (D.H.) and a developmental pediatrician with expertise in sex chromosome aneuploidy (N.T.).

The motor portion of the Clinical Rating Scale for Tremor (CRST)¹¹ and the International Cooperative Ataxia Rating Scale (ICARS)¹² were performed on each subject, with the entirety of the scales videotaped. The CRST motor portion includes objective assessment of rest, postural, and kinetic tremors, as well as objec-

tive functional rating of motor tasks. The ICARS evaluates categories including postural/gait/stance, limb movement, speech, and oculomotor. Higher scores on both of these scales imply worse tremor or ataxia. Statistical analysis to determine Pearson correlation for age and total tremor score (sum of CRST and ICARS scores) was calculated using SPSS. Family history of tremor was ascertained from the parents. Tremor frequency was measured (in Case 1 only) using the CATSYS 2000 system during a visit to UC-Davis per the protocol described in Allen et al.¹³

RESULTS

Clinical features of the patients are reported in Table 1. The mean age of the subjects was 18.3 ± 4.6 . The mean motor CRST score was 10.2 ± 1.6 and the mean total ICARS was 12 ± 1.8 . There was no significant correlation between the age of subjects and the severity of symptoms as measured by the total of the CRST and ICARS scores (Pearson $r = -0.0002$, $P = 0.99$).

Half of the subjects had a family history of tremor. There was no significant difference in CRST or total ICARS scores between groups when compared based on positive or negative family history.

Case Descriptions

Case 1

A 22-year-old left-handed male reported tremor with handwriting since age 7. He noticed the tremor when playing video games or eating. The tremor had progressively worsened over the last few years and was exacerbated by stress and sleep deprivation. A trial of atenolol 10 mg was stopped due to an episode of syncope, and a trial of primidone was discontinued due to sleepiness. Neither medication improved his tremor symptoms. He was taking propranolol 40 mg per day some improvement in his tremor. He reported balance difficulties with falling and stumbling over the prior 3–4 months.

He was diagnosed with 48,XXYY syndrome at 14 years of age due to a history of a borderline Intelligent Quotient (IQ), autism spectrum disorder, and mild dysmorphic features. He also had sleep apnea, seizures, esophageal spasms, and hypogonadism. Medications included testosterone injections, carbamazepine, methylphenidate, hyoscyamine sulfate, and cetirizine. His father and 4 uncles had tremor. Neurological examination showed persistent but moderate gaze-evoked nystagmus and mild dysarthria. He had postural and kinetic tremor (Fig. 1), with one step deviation on tan-

TABLE 1. Clinical features of 10 cases of 48,XXYY syndrome: highest CRST or ICARS score is based on highest particular item on the scale (item in parentheses)

Case	Age	Motor CRST ¹	Highest CRST ¹ score	Total ICARS ²	Highest ICARS score ²	Age at tremor onset	Family history of tremor?	Neurological exam descriptive features	Other medical features ³	Other psychological features ^{3,4}
1	22	12	2 (action tremor, handwriting)	21	2 (multiple items)	7	Yes	Kinetic and postural tremor, nystagmus, mild dysarthria	Epilepsy, sleep apnea, esophageal spasms, hypogonadism ^a	³ Borderline cognitive abilities, Autism Spectrum disorder, Obsessive-compulsive behavior, ADHD ^b —Inattentive Learning disability, ADHD—Combined anxiety disorder
2	13	18	2 (postural tremor)	20	2 (ocular pursuits, spread feet)	4	Yes	Kinetic and postural tremor, saccadic pursuits	Cystic fibrosis, G.E. reflux ^c	³ Borderline cognitive abilities, ADHD—Inattentive Learning disability, ADHD—Combined anxiety disorder
3	17	19	3 (action tremor)	13	3 (finger to nose)	10	No	Intention and postural tremor, widened stance	Scoliosis, asthma/allergies, mitral valve prolapse, hypogonadism ^a	³ Borderline cognitive abilities, ADHD—Inattentive, autism spectrum disorder, Tic disorder
4	24	10	2 (intention tremor)	15	2 (multiple items)	16	No	Mild postural and kinetic tremor, nystagmus, mild gait ataxia	Seizures in childhood, cryptorchidism, inguinal hernia repair, hypogonadism ^a	³ Learning disability, poor adaptive functioning, mood disorder
5	13	8	2 (action tremor)	10	2 (intention tremor)	3	Yes	Mild postural and kinetic tremor, dysarthria, widened stance	Strabismus, kyphosis, constipation	³ Mild intellectual disability, obsessive-compulsive disorder, mood disorder, ADHD—combined subtype
6	16	6	1 (multiple items)	8	2 (dysarthria)	12	No	Mild kinetic and postural tremor, dysarthria	Asthma/allergies, gilbert's disease, scoliosis, hypogonadism ^a	³ Borderline cognitive abilities, autistic disorder, anxiety disorder
7	26	12	2 (intention tremor)	15	2 (finger to finger, finger to nose)	15	Yes	Mild kinetic and postural tremor, dysarthria, mild gait ataxia	³ Radioulnar synostosis, seizures in childhood, strabismus, hypogonadism ^a	Mild intellectual disability, mood disorder
8	19	4	1 (multiple items)	3	1 (multiple items)	9	No	Unilateral kinetic tremor, widened stance	Hypothyroidism, pes planus, hypogonadism ^a	³ Learning disability, ADHD—Combined subtype
9	19	4	1 (multiple items)	6	1 (multiple items)	11	Yes	Mild postural and kinetic tremor, dysarthria	Asthma in childhood, hypogonadism ^a	Learning disability, anxiety disorder
10	14	9	1 (multiple items)	9	1 (multiple items)	9	No	Kinetic tremor, leg dysmetria, gait ataxia	Asthma, hypogonadism ^a	³ Learning disability, ADHD—Combined subtype

¹CRST, Clinical Rating Scale for Tremor. Higher scores indicate increased symptoms.

²ICARS, International Cooperative Ataxia Rating Scale. Higher scores indicate increased symptoms.

³This feature was noted as the primary indication for genetic testing leading to patient being diagnosed with XYY.

⁴Early speech delays were present in all patients. Seven of the ten had delayed gross motor milestones.

^aHypergonadotropic hypogonadism (testosterone deficiency) characteristic of XYY syndrome, 6/8 subjects were on testosterone replacement therapy.

^bAttention Deficit Hyperactivity Disorder.

^cGastroesophageal reflux.

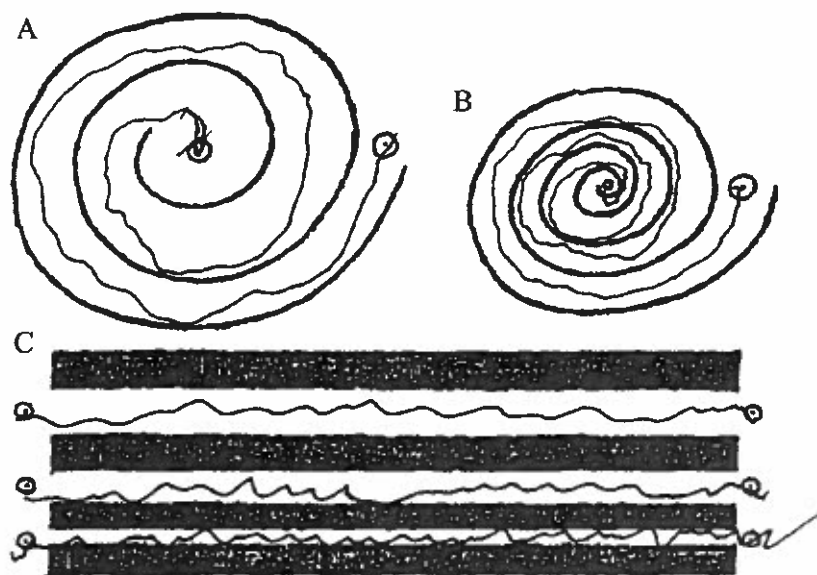


FIG. 1. Example of handwriting of spirals and lines in Case 1.

dem gait. Evaluation of his tremor using the CATSYS system showed that his tremor frequency was $6.5 \text{ Hz} \pm 1.3 \text{ Hz}$.

Case 2

A 13-year-old right-handed male presented with tremor that began at 4 years of age. He reported shaking with handwriting and eating, with worsening of tremor during times of sleep deprivation or increased stress. His medical history included a diagnosis of cystic fibrosis at 3 years of age when he presented with rectal prolapse. He was diagnosed with 48,XXYY at 7 years of age due to learning disabilities and attention deficit hyperactivity disorder. He had not been on medications for tremor, and his medications were sertraline, omeprazole, and inhaled tobramycin. Neurological examination showed saccadic ocular pursuit and postural tongue tremor. He had moderate modification of speech fluency. He had postural tremor and kinetic tremor.

Case 3

A 17-year-old right-handed male presented with shaking of the hands since 10 years of age. He noticed his hands shaking when biting his fingernails, writing, or eating ice cream. He no longer used glass cups due to the severity of tremor and the tremor worsened when he was nervous. He also reported worsening

problems with his balance. He was diagnosed with 48,XXYY syndrome at 4 years of age due to language delays. His medical history was significant for asthma, scoliosis, hypogonadism, anxiety, and autism. He had no family history of tremor. His medications included fluoxetine and testosterone gel. His examination showed saccadic ocular pursuit and postural and kinetic tremor. He had a widened stance, but was able to tandem without deviations.

DISCUSSION

In this study, 10 males with 48,XXYY were examined and had tremor of varying severity. The tremor was kinetic, postural, or both, and was usually rated as mild on the CRST. The presence of tremor in these males is consistent with other reports from our group, in which a recent review of 95 cases of 48,XXYY syndrome described kinetic tremor in 8% of individuals less than 10 years of age, 62% of individuals aged 11–20 years, and in 71% of individuals were adults.¹ In the majority of cases, the tremor most commonly begins in early adolescence. The patients in this study described worsening of tremor over time, which was corroborated by family, but this has not been studied in a longitudinal manner. There was no significant correlation between age and CRST/ICARS scores in our sample. Although the sample size was small, there were also no significant differences in CRST and

ICARS scores between those with and without a family history of tremor.

Baughman first described "essential tremor" in two 47,XXY males in 1969,⁷ and Daly described intention tremor in 10/12 males with 47,XYY.¹⁴ Tremor in 47,XYY and 47,XXY males was subsequently quantified in a blinded, controlled study using tremor recording equipment, in which physiologic tremor was found in 83% of the 47,XYY males and 64% of the 47,XXY males. Intention tremor was less frequent, although present in 50% of 47,XYY and 57% of 47,XXY.¹⁵ Based on these studies, tremor may be a common feature in the phenotype of males with sex chromosome aneuploidy, yet is often not included in clinical descriptions of these genetic syndromes.¹⁶⁻¹⁸

The tremor in sex chromosome aneuploidy is not consistent with essential tremor (ET) or other well-defined tremor disorders. The diagnostic criteria for ET require the presence of both postural and kinetic tremor, the exclusion of "other basal ganglionic disorders," the absence of psychogenic features,¹⁹ and require the exclusion of cerebellar involvement and drugs or conditions known to worsen physiologic tremor.²⁰ ET is rare in childhood (1/500 children).²¹ The age of onset of tremor, associated chromosomal abnormality, and presence of other cerebellar signs in our cases, suggest that the tremor associated with 48,XXYY is a different entity than ET.

Volumetric neuroimaging data are not yet available for 48,XXYY; however, studies in 47,XXY show a significantly decreased caudate volume compared with 46,XY (in addition to smaller frontal and temporal lobe volumes),²² as well as decreases in cerebellar lobe volumes.²³ Thus, basal ganglionic or cerebellar dysfunction may be involved in tremor symptoms in both 47,XXY and 48,XXYY. In 48,XXYY, review of 35 brain MRI's obtained for clinical reasons showed a 46% incidence of T2 white matter hyperintensities and a 23% incidence of enlarged ventricles. In that study, males with XXYY with white matter hyperintensities did not have increased rates of tremor when compared with those without white matter findings.¹

The phenotype of 48,XXYY and other forms of supernumerary sex chromosome aneuploidy are thought to result from gene dosage effects of X chromosome genes that escape X-inactivation and/or overexpression of Y chromosome genes from the extra sex chromosomes. However, the specific genes associated with the abnormal phenotypic features have not been identified. We hypothesize that tremor in 48,XXYY syndrome results from dysregulation of a sex chromosome gene, leading to altered neurodevelopment or neurophysiol-

ogy and subsequent tremor. Similar findings of tremor in both 47,XXY and 47,XYY suggest that overexpression of genes homologous on the X and Y chromosomes (pseudoautosomal regions)²⁴ are likely involved.¹⁰ Understanding gene dysregulation in 48,XXYY might serve to enhance understanding regarding the etiology of kinetic and postural tremor in these patients and other patients with sex chromosome disorders.

There are several genes on the X chromosome that have been associated with tremor in other disorders. Fragile X-associated tremor/ataxia syndrome (FXTAS) is associated with tremor, ataxia, and peripheral neuropathy due to elevated levels of mRNA from the X-chromosome *FMR1* gene in individuals with the fragile X premutation.^{25,26} Our subjects have a similar tremor and some subjects manifested cerebellar signs, such as mild gait ataxia, nystagmus, and dysarthria. However, the early age of presentation and lack of neuropathic features suggest that the tremor is caused by a different mechanism. Also, other studies suggest that the *FMR1* gene is always X-inactivated on the second X-chromosome in males with 47,XXY.^{27,28} Interestingly, a recent case report of a male presenting with atypical kinetic tremor being evaluated for FXTAS was instead found to have 47,XXY.²⁹

Other X-chromosome disorders associated with tremor are located in the Xq22-27 region, and include Pelizaeus-Merzbacher disease (mutation of the *PLP1* gene), Cabezas syndrome (X-linked mental retardation with short stature and hypogonadism; *CULAB* gene), and leukoencephalopathy with chondroplasia.³⁰⁻³² X-linked Spinal Bulbar Muscular Atrophy (Kennedy's disease) results from a polyglutamine expansion mutation in the androgen receptor gene on the X chromosome and is also associated with tremor and hypogonadism.³³ Although these disorders share some clinical features with 48,XXYY such as onset of tremor in childhood, cognitive deficits, and/or hypogonadism, they also have more significant neurological impairments and/or more progressive neurological disease than our 48,XXYY patients. The mechanism of hypogonadism is also different. Additionally, with the exception of some cases of Pelizaeus-Merzbacher disorder in which *PLP1* duplication occurs, genetic mechanisms underlying the pathophysiology of these conditions do not involve increased gene dosage. The association of hypogonadism and tremor in Cabezas syndrome and Kennedy's disease is also interesting; however, it is important to point out that 47,XYY is not associated with hypogonadism and most likely shares a common tremor pathophysiology with 48,XXYY.

Genes on the Y chromosome have not yet been linked to tremor.

Current medical practice significantly under ascertains cases of sex chromosome aneuploidy, especially in the pediatric population. It is estimated that up to 75% of individuals with 47,XXY and 88% of 47,XYY remain undiagnosed in their lifetime, with less than half of known cases diagnosed before adulthood.³⁴ These disorders are very common, with a prevalence of 1:650 for 47,XXY and 1:1,000 for 47,XYY. The 48,XXYY has a lower prevalence rate (1:18,000) and the rate of lifetime diagnosis is unknown. Clinically, the presence of tremor in a patient with a history of early developmental delays, learning disabilities, tall stature, or associated physical features such as microorchidism should prompt chromosome analysis to evaluate for sex chromosome aneuploidy. Future studies in this disorder may include prevalence and natural history studies, gene expression studies, medication trials, and direct comparison with patients with ET.

LEGENDS TO THE VIDEO

Segment 1. All three cases demonstrate postural tremor and kinetic tremor with finger-to-nose and pouring water. There was no tremor at rest.

Acknowledgments: We acknowledge grant support by Bonfils-Stanton Foundation, The XXYY Project, K23 NS052487 for D.A.H., and UC-Davis M.I.N.D. Institute. We acknowledge P. Adams for technical assistance. We thank all participants and their families. N.R.T. currently receives research support from the University of Colorado CTRC and The Children's Hospital Research Institute.

Author Roles: *Nicole Tartaglia:* Research Project: Conception, obtaining, funding, organization, and execution; statistical analysis: Execution; Manuscript: Writing and revisions. *Mariya Borodyansky:* Research Project: Organization, execution, and records review; Manuscript: Review, critique, revisions. *Deborah Hall:* Research Project: Execution; statistical analysis: Execution, video edition; Manuscript: Writing and revisions.

REFERENCES

- Tartaglia N, Davis S, Hench A, et al. A new look at XXYY syndrome: medical and psychological features. *Am J Med Genet A* 2008;146:1509–1522.
- Visoosak J, Graham JM, Jr. Klinefelter syndrome and other sex chromosome aneuploidies. *Orphanet J Rare Disease* 2006;1(42).
- Donati F, Gasser S, Mullis P, Braga S, Vassella F. 48,XXYY syndrome in a boy with essential tremor. Comparison with 120 cases from the literature. *Monatsschr Kinderheilkd* 1992;140:216–219.
- Baughman F, Mann JD. Ascertainment of seven YY males in a private neurology practice. *JAMA* 1972;222:446–448.
- Izumi S, Tsubahara A. Improvement of peripheral neuropathy by testosterone in a patient with 48,XXYY syndrome. *Tokai J Exp Clin Med* 2000;25:39–44.
- Boltshauser E, Meyer M, Deonna T. Klinefelter syndrome and neurological disease. *J Neurol* 1978;219:253–259.
- Baughman F. Klinefelter syndrome and essential tremor. *Lancet* 1969;2:545.
- Jakubowski L, Sabatowska M, Filipiak-Miastkowska I, et al. Neurological aspects of two patients with non-mosaic and mosaic polysomy of the X and Y chromosomes. *Neurol Neurochir Pol* 1999;33:169–175.
- Telfeian A, Boockvar J, Simuni T, Jaggi J, Skolnick B, Baltuch G. Efficacy of unilateral deep brain stimulation of the thalamic ventralis intermedius nucleus in a patient with bipolar disorder associated with klinefelter syndrome and essential tremor. Case report. *J Neurosurg* 2000;93:127–128.
- Deng H, Le W, Jankovic J. Genetics of essential tremor. *Brain* 2007;130:1456–1464.
- Fahn S, Tolosa E, Marin C. Clinical rating scale for tremor. In: Jankovic J, Tolosa E, editors. *Parkinson's disease and movement disorders*. Baltimore-Munich: Urban & Schwarzenberg; 1998. p 225–234.
- Trouillas P, Takayanagi T, Hallett M, et al. International cooperative ataxia rating scale for pharmacological assessment of the cerebellar syndrome. The Ataxia Neuropharmacology Committee of the World Federation of Neurology. *J Neurol Sci* 1997;145:205–211.
- Allen EG, Juncos J, Letz R, et al. Detection of early FXTAS motor symptoms using the CATSYS computerised neuromotor test battery. *J Med Genet* 2008;45:290–297.
- Daly R, Matthews C. Impaired motor function in XYY males. *Neurology* 1974;24:655–658.
- Boisen E, Rasmussen L. Tremor in XYY and XXY men. *Acta Neurol Scand* 1978;58:66–73.
- Simpson JL, Swerdloff RS, Samango-Sprouse CA, Rogol A. Klinefelter syndrome. In: *Management of Genetic Syndromes*. 2nd ed. Hoboken, NJ: Wiley-Liss, 2005. p. 323–334.
- Bojesen A, Gravholt CH. Klinefelter syndrome in clinical practice. *Nat Clin Pract* 2007;4:192–204.
- Geerts M, Steyaert J, Fryns JP. The XYY syndrome: a follow-up study on 38 boys. *Genet Counsel (Geneva, Switzerland)* 2003;14:267–279.
- Louis E, Ford B, Lee H, Andrew H, Cameron G. Diagnostic criteria for essential tremor: a population perspective. *Arch Neurol* 1998;55:823–828.
- Cersosimo M, Koller W. Essential tremor. In: Watts R, Koller W, editors. *Movement disorders*. 2nd ed. New York: McGraw-Hill; 2004. p 437–438.
- Jankovic J, Madisetty J, Vuong K. Essential tremor among children. *Pediatrics* 2004;114:1203–1205.
- Giedd JN, Clasen LS, Wallace GL, et al. XXY (Klinefelter syndrome): a pediatric quantitative brain magnetic resonance imaging case-control study. *Pediatrics* 2007;119:e232–e240.
- Lenroot RK, Shaw P, Clasen LS, Mackie S, Pierson R, Giedd JN. Comparison of cerebellar anatomy in a pediatric XXY population to XY males with and without ADHD. *J Intellect Disabil Res* 2007;51:655.
- Graves JA, Wakefield MJ, Toder R. The origin and evolution of the pseudoautosomal regions of human sex chromosomes. *Hum Mol Genet* 1998;7:1991–1996.
- Hagerman PJ, Hagerman RJ. Fragile X-associated tremor/ataxia syndrome (FXTAS). *Ment Retard Dev Disabil Res Rev* 2004;10:25–30.
- Berry-Kravis E, Goetz CG, Leehey MA, et al. Neuropathic features in fragile X premutation carriers. *Am J Med Genet A* 2007;143:19–26.
- Paduch D. Faststart high fidelity PCR system simplifies study of epigenetics and DNA methylation. *Biochemica* 2005;2:19.
- Pena SD, Sturzeneker R. Molecular barr bodies: methylation-specific PCR of the human X-linked gene FMR-1 for diagnosis